

# The Effect of Deslorelin Acetate in the Treatment of Persistent Urinary Incontinence After Operation of Ectopic Ureterin a Golden Retriever Bitch

Çağrı GÜLTEKİN<sup>1</sup> Eser ÖZGENCİL<sup>1</sup> Deniz SEYREK-İNTAŞ<sup>2</sup>

<sup>1</sup> Department of Surgery, Faculty of Veterinary Medicine, University of Near East, Near East Boulevard, 99138, Nicosia, TURKISH REPUBLIC OF NORTHERN CYPRUS

<sup>2</sup> Department of Surgery, Faculty of Veterinary Medicine, University of Uludağ, TR-16059 Bursa - TURKEY

Article Code: KVFD-2015-14628 Received: 04.11.2015 Accepted: 18.12.2015 Published Online: 07.01.2015

## Abstract

In this report, deslorelin acetate (suprelorin) implant, a GnRH depot analogue, was used for the first time in postoperatively observed urinary incontinence treatment of one year old female Golden Retriever puppy which came to our hospital with urinary incontinence complaint, diagnosed with left unilateral extramural ectopic ureter, treated for her ectopic ureter with ureteroneocystostomy operation and undergone ovariohysterectomy operation at the same time. In the examination at the end of eight months of postoperative period, it was observed that urinary incontinence which was thought to be due to urinary sphincter deficiency following the ectopic ureter surgery has been completely disappeared. The positive effect of deslorelin acetate on the treatment of urinary incontinence after ovariohysterectomy, which was reported in the literature in a limited number, was also found to be effective in the treatment of urinary sphincter deficiency, which was frequently observed following the ectopic ureter surgery.

**Keywords:** Ureteral ectopi, Dog, Deslorelin acetate, Urinary incontinence, Urethral sphincter mechanism incompetence

## Bir Dişi Golden Retrieverda Ektopik Üreter Operasyonu Sonrası Kalıcı Üriner İnkontinensin Tedavisinde Deslorelin Asetatın Etkisi

## Özet

Bu raporda ürinerinkontinens şikayeti ile hastanemize getirilen ve sol unilateral ektramural ektopik üreter tanısı konarak üreteroneocystostomi operasyonu ile ektopiküreteri onarılan ve aynı anda ovariohisterektomi operasyonu da geçiren 1 yaşlı, dişi Golden Retriever yavrusunda gözlenen postoperatif üriner inkontinensin tedavisinde ilk kez kullanılan GnRH depotanalogue deslorelinacetate (suprelorin) implantının etkinliği ele alındı. Postoperatif sekizinci ayda yapılan muayenelerde ektopiküreter operasyonunu takiben ürinerinkontinensin kaynağı olduğu düşünülen ürinerinkontinensin tamamen ortadan kalktığı gözlemlendi. Ovariohisterektomi sonrası ürinerinkontinens tedavisindeki etkinliği önceden bilinen deslorelin asetatın, ektopiküreter operasyonunu takiben sıklıkla gözlenen ürinerinkontinensin tedavisinde de etkili olduğu düşünüldü.

**Anahtar sözcükler:** Ektopik üreter, Köpek, Deslorelinacetate, Üriner inkontinens, Üretral sfinkter yetmezliği

## INTRODUCTION

Ectopic ureter (EU) is defined as a ureteral opening that enters the urinary tract in any location other than the trigone of the bladder and is the most common cause of urinary incontinence (UI) in young dogs. It has been reported that Golden Retriever, Labrador Retriever, Siberian Husky, Newfoundland, and English Bulldog breeds were to be at risk include the EUs<sup>[1]</sup>. EUs are classified as extramural (eEU) or intramural (iEU) depending on their anatomic course in dogs<sup>[2,3]</sup>. EU may be associated with other urogenital

abnormalities such as hydronephrosis (HU), hydronephrosis (HN), urethral sphincter mechanism incompetence (USMI), vestibulovaginal malformations, hypoplastic bladder or kidney<sup>[2-4]</sup>, urinary tract infections (UTI), renal dysplasia, short urethras, persistent paramesonephric remnants and vaginal septum or dual vaginas<sup>[5]</sup>.

Ectopic ureters can be diagnosed with contrast radiography, excretory urography, abdominal ultrasonography, cystoscopy, helical computed tomography, or a combination of these diagnostic procedures<sup>[3,6]</sup>. Contrast radiographic



İletişim (Correspondence)



+90 533 8473930



cagri.gultekin@neu.edu.tr

studies, including excretory intravenous urography (IVU) and retrograde contrast vaginourethrocytography may reveal EUs, but identification of both ureteral openings is often not possible [7,8].

Surgical procedures, which are aimed at repositioning the ureteral orifice(s) within the bladder lumen and treating primary sphincter incompetence, are necessary to successfully manage small animal patients with ectopic ureters [9]. If the ureter is extraluminal, ureteroneocystostomy must be performed by resecting the ureter as distal as possible and reimplanting in the bladder lumen [1,3].

Generally postoperative persistent UI can be managed in many cases pharmacologically with the alfa adrenergic stimulant phenylpropanolamine or estrogen compounds that increase sensitivity of alfa-adrenergic receptors in the urethra [1]. The daily supplementation of oestrogen only results in 61-65% of incontinent bitches becoming continent [10]. Unfortunately phenylpropanolamine is not completely effective in the treatment USMI [11,12]. Recently gonadotropin-releasing hormone (GnRH) analogues were shown to improve continence in ovariectomized female dogs [1,13,14].

With this report, in a Golden Retriever female dog treated with submucosal tunnel technique and diagnosed left unilateral eEU by the help of plain and contrast radiography was evaluated ultrasonographic and subjectively regressing of postoperative UI with the using GnRH depot analogue (deslorelin acetate 9.4 mg; Suprelorin, Virbac, France) implante previously unused for this purpose.

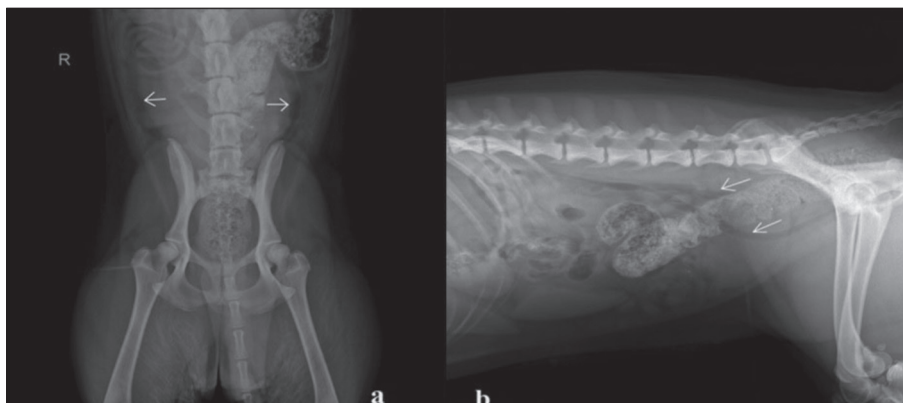
## CASE HISTORY

A 1-year-old female intact Golden Retriever bitch was referred to Animal Teaching Hospital, Faculty of Veterinary Medicine, Near East University-Turkish Republic of Northern Cyprus with a history of UI. The owner complained that the bitch had been incontinent since purchasing her as a 1-month-old puppy. The clinical examination was normal except for serious perivulvar dermatitis and odor. Blood, serum and urine samples were collected for hematologic, biochemical and urine analysis. Hematologic

and biochemical results from serum samples showed no any abnormality. In urine analysis, it was detected that the urine was yellow and blurry, specific gravity was 1020, pH was 8.0. There was (++) positive erythrocytes and (+++) positive leucocytes and (+) positive nitrate in the urine test strip. In microscopic evaluation of urine sample, it was noted that there were 50-100 leucocytes and 5-20 erythrocytes in microscopic field (40x magnification). UTI was diagnosed according to laboratory parameters and under controlled by the antibiotherapy with Ciprofloxacin (Cipro 500 mg, Biofarma) 11 to 15 mg/kg per day and 11 to 20 mg of Amoxicillin and 2.75 to 5 mg of Clavulanic acid (Synulox 500 mg, Zoetis) per kg of body weight every eight to twelve hours orally.

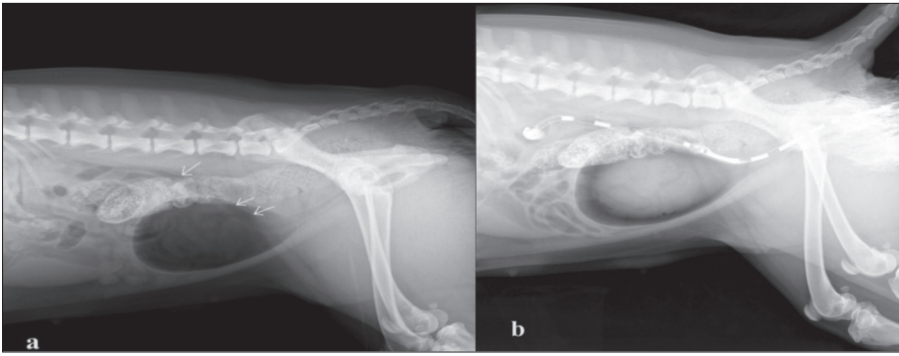
To evaluate cause of UI with plain and contrast radiography the dog was sedated. In the latero lateral (L/L) and ventro dorsal (V/D) plain radiographic evaluation; bilateral HU and mild HN were also present (Fig. 1). Dilated EU was clearly demonstrable with L/L pelvic negative and double contrast cystography (Fig. 2). The dog under the general anaesthesia was positioned in dorsal recumbency for a ventral midline laparotomy and during the abdominal explanation, it was observed that right ureter has been entered the dorsolateral caudal surface of the bladder and empties into the trigone normally but had dilated, left ureter has been bypasses the bladder to enter urethral lumen extramurally and dilated much more than right ureter (Fig. 3). Left eEU was corrected ureteroneocystostomy operation using submucosal tunnel technique (Fig. 4). In the same time ovariohysterectomy operation was performed in order to prevent overpopulation and at the request of the owner.

At the end of the examination and interviews with the owner after 20 days postoperatively, UI are determined decreased by 50% compared to preoperative period. In the UI treatment is thought to be originated of USMI, GnRH depot analogue deslorelin acetate (suprelorin) implant was used instead of the classical medicaments using treatment of urinary incontinence. An implant containing 9.4 mg deslorelin (Suprelorin, Virbac, France) was administered subcutaneously in the interscapular region by using a single use applicator. The dog was evaluated radiographically,



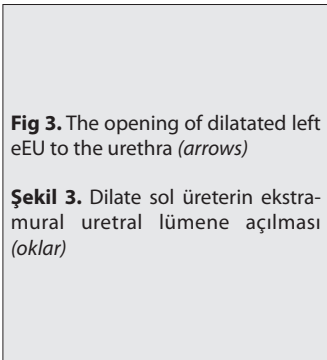
**Fig 1.** Latero lateral (L/L) and ventro dorsal (V/D) plain radiographic imaging of bilateral HU (arrows) and mild HN

**Şekil 1.** Bilateral HU (oklar) ve orta dereceli HN laterolateral (L/L) ve ventrodorsal (V/D) radyografik görüntüsü



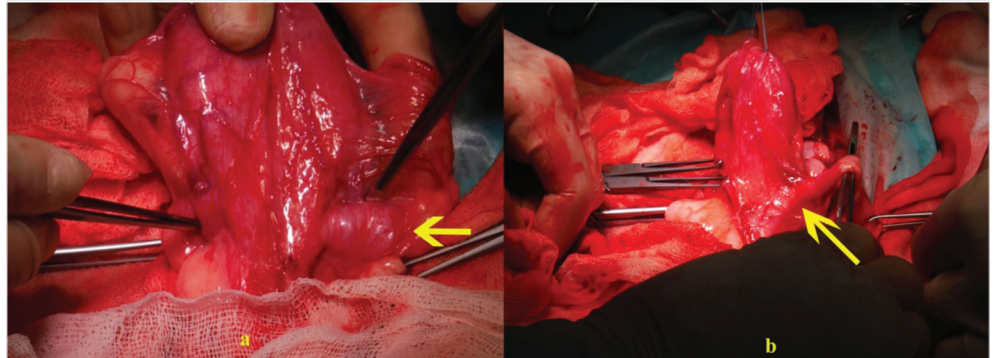
**Fig 2.** Dilatated eEU was clearly demonstrable with L/L pelvic negative and double contrast cystography (*arrows*)

**Şekil 2.** Latero lateral (L/L) pelvik negatif ve çift kontrast sistografide dilate eEU görüntüsü (*oklar*)



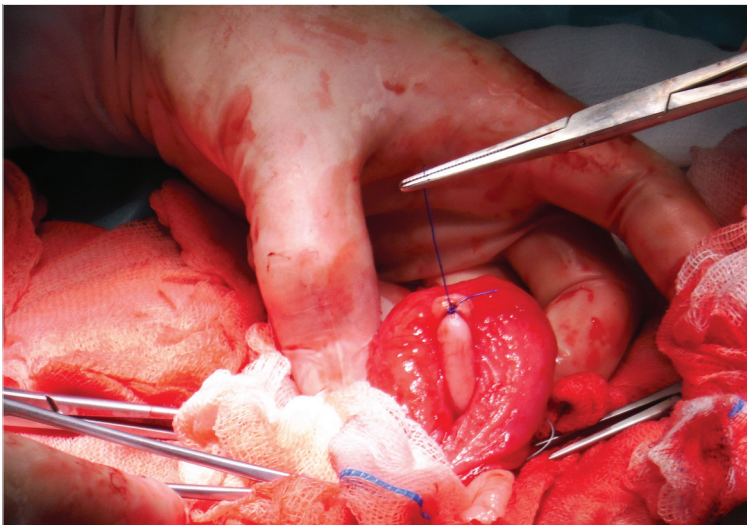
**Fig 3.** The opening of dilatated left eEU to the urethra (*arrows*)

**Şekil 3.** Dilate sol üreterin ekstramural uretral lümene açılması (*oklar*)



**Fig 4.** Left eEU was corrected ureteroneocystostomy operation using submucosal tunnel technique

**Şekil 4.** Submukozal tünel tekniği kullanılarak sol eEU'nun üretroneosistostomi operasyonu ile düzeltilmesi



ultrasonographically and subjectively each month. In the first month after the implant was placed, it was observed that narrowing of the diameter of the left ureter and regressing of HN. At the end of interviews with owner, UI are determined regressing by 90% compared to before period in the second month. In the examination after 8 months, it was observed that UI completely disappeared. The positive effect of deslorelin acetate on the observed UI after OHE was also effective in the improvement of UI observed following the ectopic ureter operation.

## DISCUSSION

It has known that the EUs resulting in inappropriate

ureteral tube termination and malposition of the ureteral orifice [5] were heritable condition in the Golden Retriever females and males [1,7,15,16]. In the study of Reicher et al.[2] related with EU cases, they indicated early start of UI, observation of a higher incidence of left unilateral EU and that urethra shaping of urethral opening is usually more common in females than in males; and the data were consistent with the data of our case.

Suspected bladder and urethral functional anomalies, such as USMI, have been reported in 75 to 89 percent of female dogs [5] and the most common clinical sign associated with EU was UTI[2].Dilatation of the renal pelvis and hydroureter may be associated with maldevelopment of structures or acquired infection [16]. It has been



reported that the affected female Golden puppies did not grown as rapidly nor were as active as other litter members, as they were very prone to bacterial infections<sup>[7]</sup>. Postoperative complications have been included persistent incontinence, hydronephrosis, and the risks associated with open abdominal surgery and urinary incontinence is the most common clinical sign in dogs with EU<sup>[1,3,16]</sup>. In our case, UI, HU, HN and UTI were determined in addition to EU. UTI and UI taken under control with the repair of EU and antibiotherapy were observed within the significant findings. In one-year-old phenomenon, UTI antibiotherapy determined as a result of laboratory and urine tests was taken under control with EU operative treatment and it was verified with laboratory and urine analysis that treatment of EU and incontinence has a big contribution on not repeating in postoperative period.

The first step in the treatment of incontinence patients is alpha-adrenergic agonists (which are commonly used to stimulate the alpha-adrenergic receptors expressed in the internal urethral sphincter, leading to an increase in the urethral closure pressure). The success rate varies from 86% to 97% for phenylpropanolamine and 74-93% for ephedrine. But the use of alpha-adrenergic agonists is contraindicated in diseases where an increase in blood pressure should be avoided, as in most kidney diseases, heart problems or glaucoma<sup>[13,14]</sup>. The subcutaneous application of GnRH depot analogues (Deslorelinacetate 4.7 mg/dog) increases bladder compliance and is successful as a single therapy in approximately 50% of bitches with UI. GnRH analogues are especially suitable for patients showing serious side effects after therapy with alpha-adrenergic agonists or if alpha-adrenergic agonists are contraindicated. So far, there have been no reports on side effects after the use of GnRH analogues in ovariectomized bitches<sup>[13]</sup>. In the literature, GnRH depot analogue was reported to have restored incontinence only in castrated male dog<sup>[17]</sup> and cat<sup>[18]</sup>. In our case, it was observed that urinary incontinence thought to be caused from OHE or USMI which continues after OHE done with ectopic ureter correction was removed with deslorelin acetate implant, reported as GnRH agonist in a limited number in the literature, in a 7-month period. Unlike the side effects of other drugs, no adverse effects of deslorelin acetate were determined and it was examined that deslorelin acetate was successful in a case of the treatment of USMI-induced urinary incontinence and intending to support further research will be appropriate.

## REFERENCES

- Davidson AP, Westrop JL:** Diagnosis and management of urinary ectopia. *Vet Clin North Am: Small Anim Pract*, 44, 343-353, 2014. DOI: 10.1016/j.cvsm.2013.11.007
- Reichler IM, Specker EC, Hubler M, Boos A, Haessig M, Arnold S:** Ectopic ureters in dogs: clinical features, surgical techniques and outcome. *Vet Surg*, 41,515-522, 2012. DOI: 10.1111/j.1532-950X.2012.00952.x
- Fossum TW:** Surgery of the kidney and ureter - Ectopic ureter. In, Fossum TW (Ed): *Textbook of Small Animal Surgery*. 3<sup>rd</sup> ed., 635-663, St. Louis, MO, Mosby, 2007.
- Holt PE, Moore AH:** Canine ureteral ectopia: An analysis of 175 cases and comparison of surgical treatments. *Vet Rec*, 136 (14): 345-349, 1995.
- Weisse C, Berent A:** Correcting ectopic ureters in juvenile dogs: Cystoscopic-guided laser ablation is a minimally invasive alternative to surgery. <http://veterinarynews.dvm360.com/correcting-ectopic-ureters-juvenile-dogs>. Accessed: 01.04.2015.
- Lamb CR, Gregory SP:** Ultrasonographic findings in 14 dogs with ectopic ureter. *Vet Radiol Ultrasound*, 39 (3): 218-223,1998.
- HedburgK:** Ectopic Ureter in Golden Retrievers. [http://www.australiangoldenretrieverbreeders.com/assets/ectopic\\_ureter\\_in\\_golden\\_retrievers\\_karen\\_hedburg.pdf](http://www.australiangoldenretrieverbreeders.com/assets/ectopic_ureter_in_golden_retrievers_karen_hedburg.pdf), Accessed: 30.04.2015.
- Özgenicil E, Beşaltı Ö:** Ureteral ectopia in two Dalmatian bitches. *Turk J Vet Anim Sci*, 21, 503-506, 1997.
- McLoughlin MA, Chew DJ:** Diagnosis and surgical management of ectopic ureters. *Clin Tech Small Anim Pract*, 15, 2000.17-24, DOI:10.1053/svms.2000.7302
- Arnold S, Arnold P, Hubler M, Casal M, Rusch P:** Incontinentiaurinaebei der kastriertenHu`ndin:Ha`ufigkeitund Rassedisposition. *Schweiz Arch Tierheilkd*, 131, 259-263,1989.
- Arnold S, Hubler M, Reichler I:** Urinary incontinence in Spayed bitches: New insights into the pathophysiology and options for medical treatment. *Reprod Dom Anim*, 44 (Suppl. 2): 190-192, 2009. DOI: 10.1111/j.1439-0531.2009.01407.x.ISSN 0936-6768
- Scott L, Leddy M, Berney F, Davot JL:** Evaluation of phenylpropanolamine in the treatment of urethral sphincter mechanism incompetence in the bitch. *J Small Anim Pract*, 43, 493-496, 2002.
- Reichler IM, Hubler M:** Incontinence in the bitch: An update. *Reprod Dom Ani m*, 49 (Suppl. 2): 75-80, 2014. DOI: 10.1111/rda.12298
- Ponglowhapan S, Khalid M, Church D:** Canine urinary incontinence post-neutering: A review of associated factors, pathophysiology and treatment options. *Thai J Vet Med*, 42 (3): 259-265, 2012.
- Hayes HM:** Breed associations of canine ectopic ureter: A study of 217 female cases. *J Small Anim Pract*, 25, 501-504, 1984.
- Cannizzo KL, McLoughlin MA, Mattoon JS, Samii VF, Chew DJ, DiBartola SP:** Evaluation of transurethral cystoscopy and excretory urography for diagnosis of ectopic ureters in female dogs: 25 cases (1992-2000). *Am Vet Med Assoc*, 223, 475-481, 2003.
- Greer M:** Deslorelin implant for urinary incontinence treatment in a neutered male dog, a case study. *7<sup>th</sup>International Symposiumon Canineand Feline Reproduction*. July 26 to 29, 2012. Whistler, Canada. <http://www.ivis.org/proceedings/iscfr/2012/62.pdf?LA=1>, Accessed: 22.09.2015.
- Pisu MC, Veronesi MC:** Effectiveness of deslorelin acetate subcutaneous implantation in a domestic queen with after-spaying urinary incontinence. *J Feline Med Surg*, 16, 366-368, 2013. DOI: 10.1177/1098612X13498250