

Active Implant Periapical Lesions Leading to Implant Failure: Two Case Reports

Oğuz Buhara, DDS
Lokman Onur Uyanık, DDS, PhD*
Aysa Ayali, DDS
Melek Aydın, DDS

Implant periapical lesion (IPL), an inflammatory lesion surrounding the apex of a dental implant, has been previously reported as a possible cause for implant failure. This article describes 2 successive cases of active IPL that were diagnosed early by clinical signs and radiologic findings. Lesions were treated surgically with implant removal and debridement. The etiology, findings, and treatment approaches for IPL are discussed in comparison with other reports.

Key Words: *implant periapical lesion, implant failure*

INTRODUCTION

Implant periapical lesion (IPL) has been described as an inflammatory lesion involving the apical portion of a dental implant.^{1,2} It is also known as apical or retrograde peri-implantitis, and it was first introduced by McAllister et al in 1992.³ In addition, IPL has been reported to interfere with the osseointegration process, and progression of the lesion may cause implant failure.⁴⁻⁸

The etiology of IPL has been described as having a multifactorial background. Proposed factors that induce IPL formation include bone overheating, bacterial contamination of the implant surface, presence of preexisting pathology, and poor bone quality.^{6,9,10}

Diagnosis of IPL is based on clinical signs such as pain, tenderness, swelling, and fistulous tract formation; radiographic findings such as periapical radiolucency may also be present.^{4,5} When the radiographic findings are not associated with clinical symptoms, it is considered to be inactive and no treatment is needed if they remain stable in

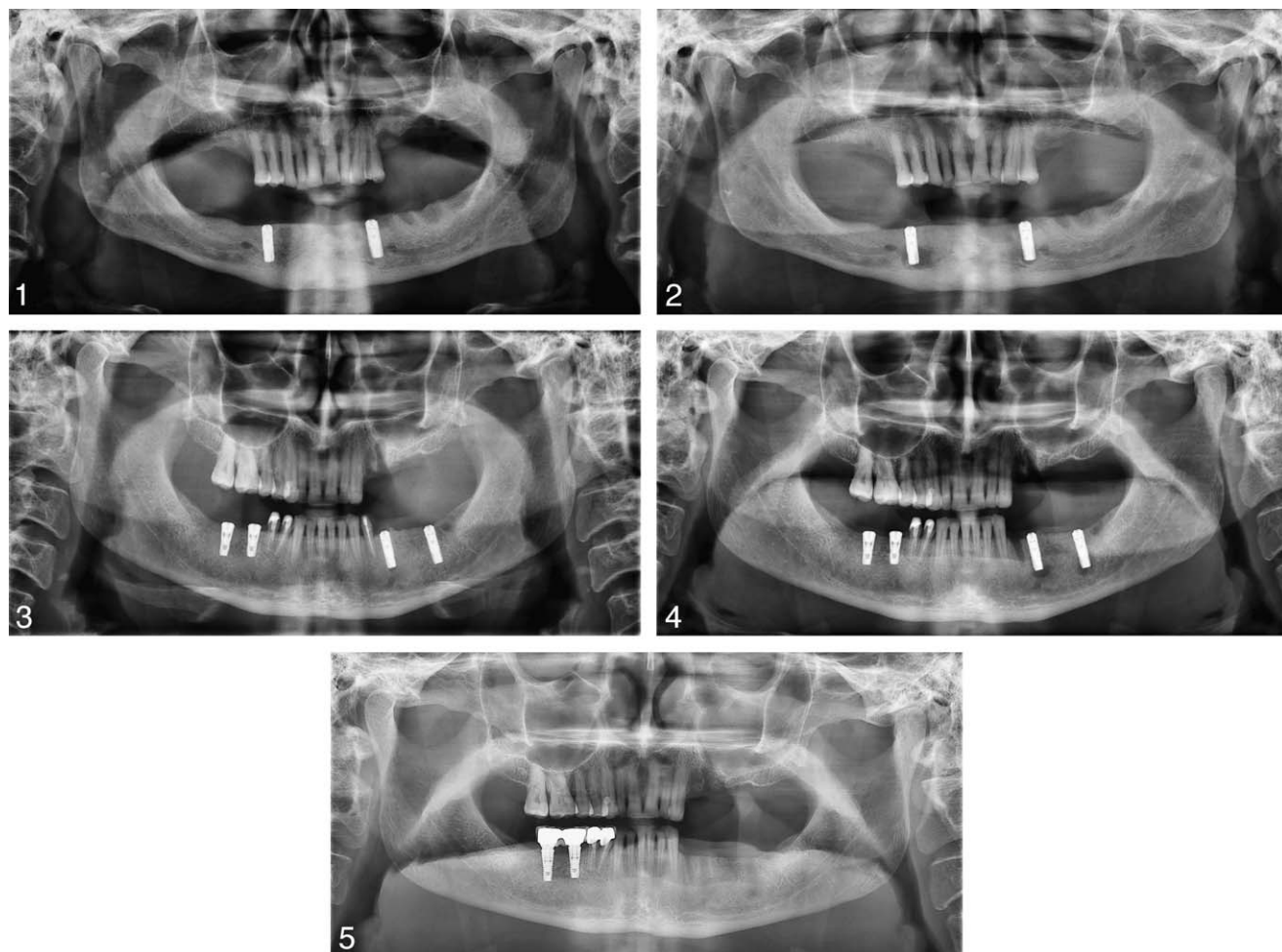
the periodic follow-ups. On the other hand, active infected lesions are expansile and grow by time.^{1,9} Active lesions are also capable of spreading coronally or laterally, and they are usually accompanied by clinical symptoms.^{1,4,10} For the treatment of the active IPL, surgical approaches have been suggested, including implant removal, apicoectomy, curettage, and guided tissue regeneration.^{2,5,7,8}

The aim of this article is to describe 2 interesting cases of IPL that occurred successively and that resulted in failure of 4 implants. In addition, possible etiology and treatment options will be discussed.

CASE REPORTS

Two cases are presented. The patients underwent surgery on consecutive days by different surgeons in the same operating room of Department of Oral and Maxillofacial Surgery. Four 13 × 4.0 mm Astra Tech implants (Astra Tech Dental, Mölndal, Sweden) were placed in the 2 patients. Both patients demonstrated type 2 bone quality. A 2-stage surgical procedure was planned without the use of an interim prosthesis in each case. The implants had never been loaded during the first stage of the treatment. After surgery, both patients were asked to rinse with an antimicrobial mouth rinse. Patients were also prescribed a nonsteroidal anti-inflamma-

Department of Oral and Maxillofacial Surgery, School of Dentistry, Near East University, Nicosia, North Cyprus.
* Corresponding author, e-mail: lokmanonur@gmail.com
DOI: 10.1563/AAID-JOI-D-11-00127



FIGURES 1–5. FIGURE 1. Case 1: Panoramic x-ray view immediately after dental implant placement. **FIGURE 2.** Case 1: Panoramic radiograph showing radiolucencies involving the apex of the 2 implants. **FIGURE 3.** Case 2: Radiograph taken after placement of 2 implants on the left side. **FIGURE 4.** Case 2: Panoramic view showing radiolucent lesions surrounding the apex of the implants on the left side. **FIGURE 5.** Case 2: Radiographic image 2 months after implant removal, showing ongoing healing and resolution of the lesions.

tory drug (naproxen sodium) and a systemic antibiotic (amoxicillin).

Case 1

A 62-year-old man with no relevant past medical history attended our clinic for implant-supported prosthetic rehabilitation. He presented with an edentulous mandible. On December 6, 2 implants were inserted into the areas of tooth no. 22 and tooth no. 27 under local anesthesia, following the basic surgical principles and manufacturer’s instructions (Figure 1). Twenty days after placement, the patient returned to the department with a dull pain only over the right mandibular canine area; he stated that the pain started the first week after surgery.

Radiographically, we observed radiolucencies in the periapical regions of both implants (Figure 2). There was no sign of swelling or fistulation. We prescribed antibiotics (clindamycin). Three days later both implants were surgically removed, and the site was carefully curetted under profuse sterile irrigation. The implants and other specimens collected from the socket were sent to the laboratory for microbiological evaluation. According to the results no bacterial colonization was found.

Case 2

A 55-year-old healthy woman presented with a partially edentulous lower jaw. On December 7, tooth no. 20 was extracted and an implant was immediately inserted into the socket of that tooth.

An implant was also inserted into the region of tooth no. 18 (Figure 3). The day after surgery she developed unusual pain, which she described as excruciating, and was feeling very uncomfortable. Seven days after surgery tooth no. 21, which was seen as a possible cause of the persistent pain, was extracted in accordance with the patient's request because she could no longer bear the pain. We were unable to link this unusual pain to a more significant source. We also administered systemic antibiotics (clindamycin).

Seven days later the patient was still in pain. We obtained a cone beam computerized tomography scan (CBCT) to detect any possible problems, but the CBCT imaging revealed no abnormality at the implant site. We also applied low-level laser therapy using diode laser (LaserSmile, Biolase, Irvine, Calif) to relieve the patient's pain. There was no pain relief at the third week. Then we took another x-ray (panoramic) and noticed periapical radiolucencies at the apex of the implants (Figure 4). There was no swelling and fistulation. For treatment, both implants were surgically removed, and the site was completely debrided. The microbiological findings from the implant surface and specimens showed no bacterial growth.

Case Resolution

After implant removal, the persistent pain disappeared completely in both patients and healing was uneventful.

DISCUSSION

Diagnosis

Research suggests that IPL is a rarely seen complication and a possible cause of early implant failure.^{1,2,4} Clinical symptoms, along with radiographic findings, provide the information needed to diagnose IPL.^{2,9}

In our report the symptoms appeared in the first week after surgery. In case 2, the patient had complained of continuing, excruciating pain, which usually increased at night. Physical examination revealed sensitivity to palpation of the mucosal soft tissues over the implant no. 20. These clinical symptoms are similar to findings described in other reports.^{2,4,8,11} Until the third week there was no radiographic evidence of any pathology on the

CBCT and panoramic scans. Based on these early findings, there was no doubt that the patients were presenting symptoms of an acute pathology. Unlike other reports,^{4,5,7,8,10} we recorded no fistulas in our patients, which supports the idea of active IPL.

Three weeks after implant placement, we observed periapical lesions on panoramic radiographs in both patients. Although some authors^{2,10} reported that they discovered the lesions earlier, such as the first week after surgery, several cases have been reported years after the surgical placement.^{4,8,12}

Etiology

The etiopathogenesis of active IPL remains controversial, but it is believed to have a multifactorial origin. It has been suggested that these lesions may result from implants replacing teeth with a history of periapical pathology, failed endodontic treatment, and/or apicoectomy.^{1,4,10,11,13} According to Ayangco and Sheridan,¹³ bacteria would have persisted around endodontically compromised teeth, and such a situation can lead to early contamination of an implant surface. Some authors have also suggested that a preexisting pathology, such as granulomas or residual cysts, may also contribute to the initiation of IPL.^{1,3,7,10,11} In case 1, the patient had had an edentulous mandible for a long time, until just before implant placement. Hence, the lesions seemed not to be related with this proposal. In case 2, one of the implants immediately replaced an endodontically treated, problematic tooth. However, microbiological evaluation showed no bacterial colonization, disproving the possible contamination factor mentioned earlier.

Scarano et al¹¹ and Peñarrocha-Diago et al² suggest that IPL may occur because of contamination during instrumentation with regard to the potential cross-contamination risk due to inadequate sterilization of the surgical kit, in our report it is suspicious that the second patient was treated on the day after first patient was treated. However, this idea still does not explain the occurrence of IPL in the first patient.

Another possible factor reported for IPL is poor bone quality, which can have a negative influence on the formation of mineralized tissues around the implant.^{1,11} Most of the IPLs reported were in maxillary locations, where the bone quality tends to be poor.⁹ However, IPLs in our patients were in

mandibular locations, and the bone quality was sufficient for normal bone healing. Therefore, it is believed to have played a small role in the formation of IPL in our patients.

Some authors have suggested that such periapical lesions may be secondary to overheating of the bone during surgery, which can result in necrosis around the apex of the implants.^{1,6,14} This hypothesis corresponds well with our findings if we consider the fact that the second patient had previously had implants successfully placed on her lower right side. These 2 healthy implants belong to the same implant system. The only difference is that they were shorter than the implants that failed because of IPL on the other side. Also, patient 1 had 2 implants of the same length that failed due to IPL. With the increased drilling depth, the bone might have overheated, as it is more difficult to maintain adequate cooling. Inadequate irrigation may be a consequence of irrigant solution blockage as it passes to the working tip, due to calibration errors of the surgical equipment.¹⁴ This situation seems to justify the relation between the drilling depth and bone overheating that leads to IPL formation. Therefore, we suggest that excessive heating of bone is the most likely cause of IPL in our patients.

Treatment

Several therapeutic alternatives have been demonstrated for the treatment of IPL, including curettage or debridement along with implant apicoectomy,^{2,4,13} guided tissue regeneration with bone grafting,^{2,8,10} and systemic antibiotics and implant removal.^{5,6,7,11,15} In the cases presented here, we initially prescribed systemic antibiotics but observed no response to this therapy in accordance with the other reports.^{2,4} Antibiotic administration alone is unsuccessful in resolving the IPL.^{7,9} Therefore, we agree that surgical debridement or removal of infection sources, including contaminated implants and periapical lesions, is essential.^{7,15} However, a recent report by Chang et al¹⁶ indicates that IPL can be successfully treated by systemic medications only.

In case 2, where the patient had described a severe pain radiating to her head even after the extraction of tooth no. 21, we also applied low-level laser therapy, which has been found to be beneficial for reducing postoperative pain.¹⁷ Low-level laser was applied (dose = 3 j/cm², λ = 810 nm, diode

laser) for a week with an interval of 2 days to relieve the supposed postoperative pain, but it also failed to subside the patient's discomfort. After a while we realized that IPL was responsible for all of those symptoms and this was why low-level laser therapy had not worked.

In both cases reported here, we observed fast lesion growth when we compared the radiographs taken at the second and third weeks. The periapical lesions were active and had potent capacity to spread rapidly; sufficient integration of the implants had not yet been achieved. Also, the patients were complaining that the persistent pain was affecting their daily life. Therefore, we decided to remove the implants and perform thorough debridement. The goals of this treatment are to arrest the rapid progression of the lesion before it damages the vital structures, to provide definitive healing of the bony defects, and to resolve the continuous pain. All the clinical symptoms disappeared after treatment and the lesions diminished in size as shown on the radiographs taken 2 months after treatment (Figure 5).

Although IPL is a rarely seen pathology, it remains a valid threat to the success of the dental implant treatment. To achieve a successful implant treatment and to minimize such complications as IPL, basic surgical principles should be followed. Standardized surgical instruments should be used in accordance with the manufacturer's recommendations. In addition, internal irrigation drilling systems can be used to prevent bone overheating. One should keep in mind that severe persistent pain after implant surgery may be an early finding of IPL, as seen in our patients. Careful clinical and radiographic assessment and detailed treatment planning are crucial for the long-term success of the dental implants. More studies and data are needed to reach a consensus concerning the exact etiology and optimal treatment guidelines for implant periapical lesions.

ABBREVIATION

IPL: implant periapical lesion

REFERENCES

1. Reiser GM, Nevins M. The implant periapical lesion: etiology, prevention, and treatment. *Compend Contin Educ Dent.* 1995;16:768, 770, 772.
2. Peñarrocha-Diago M, Boronat-Lopez A, Garcia-Mira B.

Inflammatory implant periapical lesion: etiology, diagnosis, and treatment—presentation of 7 cases. *J Oral Maxillofac Surg.* 2009;67:168–173.

3. McAllister BS, Masters D, Meffert RM. Treatment of implants demonstrating periapical radiolucencies. *Pract Periodontics Aesthet Dent.* 1992;4:37–41.

4. Dahlin C, Nikfarid H, Alsén B, Kashani H. Apical peri-implantitis: possible predisposing factors, case reports, and surgical treatment suggestions. *Clin Implant Dent Relat Res.* 2009;11:222–227.

5. Silva GC, Oliveira DR, Vieira TC, Magalhães CS, Moreira AN. Unusual presentation of active implant periapical lesions: a report of two cases. *J Oral Sci.* 2010;52:491–494.

6. Piattelli A, Scarano A, Piattelli M, Podda G. Implant periapical lesions: clinical, histologic and histochemical aspects. A case report. *Int J Periodontics Restorative Dent.* 1998;18:181–187.

7. Oh TJ, Yoon J, Wang HL. Management of the implant periapical lesion: a case report. *Implant Dent.* 2003;12:41–46.

8. Tözüm TF, Sençimen M, Ortakoğlu K, Ozdemir A, Aydin OC, Keleş M. Diagnosis and treatment of a large periapical implant lesion associated with adjacent natural tooth: a case report. *Oral Surg Oral Med Oral Pathol Oral Radiol Endod.* 2006;101:e132–e138.

9. Romanos G, Froum S, Costa-Martins S, Meitner S, Tarnow D. Implant periapical lesions: etiology and treatment options. *J Oral Implantol.* 2011;37:53–63.

10. Quirynen M, Vogels R, Alsaadi G, Naert I, Jacobs R, van

Steenberghe D. Predisposing conditions for retrograde peri-implantitis, and treatment suggestions. *Clin Oral Implants Res.* 2005;16:599–608.

11. Scarano A, Di Domizio P, Petrone G, Iezzi G, Piattelli A. Implant periapical lesion: a clinical and histologic case report. *J Oral Implantol.* 2000;26:109–113.

12. Jalbout ZN, Tarnow, DP. The implant periapical lesion: four case reports and review of the literature. *Pract Proced Aesth Dent.* 2001;13:107–112.

13. Ayangco L, Sheridan PJ. Development and treatment of retrograde peri-implantitis involving a site with a history of failed endodontic and apicoectomy procedures: a series of reports. *Int J Oral Maxillofac Implants.* 2001;16:412–417.

14. Palmer BM, Smith BJ, Howe LE, Palmer PJ. Basic factors in implant surgery. In: *Implants in Clinical Dentistry.* London: Martin Dunitz Ltd; 2002:85, 237.

15. Sussman HI. Periapical implant pathology. *J Oral Implantol.* 1998;24:133–138.

16. Chang LC, Hsu CS, Lee YL. Successful medical treatment of an implant periapical lesion: a case report. *Chang Gung Med J.* 2011;34:109–114.

17. Kreisler MB, Haj HA, Noroozi N, Willershausen B. Efficacy of low level laser therapy in reducing postoperative pain after endodontic surgery—a randomized double blind clinical study. *Int J Oral Maxillofac Surg.* 2004;33:38–41