

# Kafa Derisi ve Yüzün Yüzeyel Yapıları

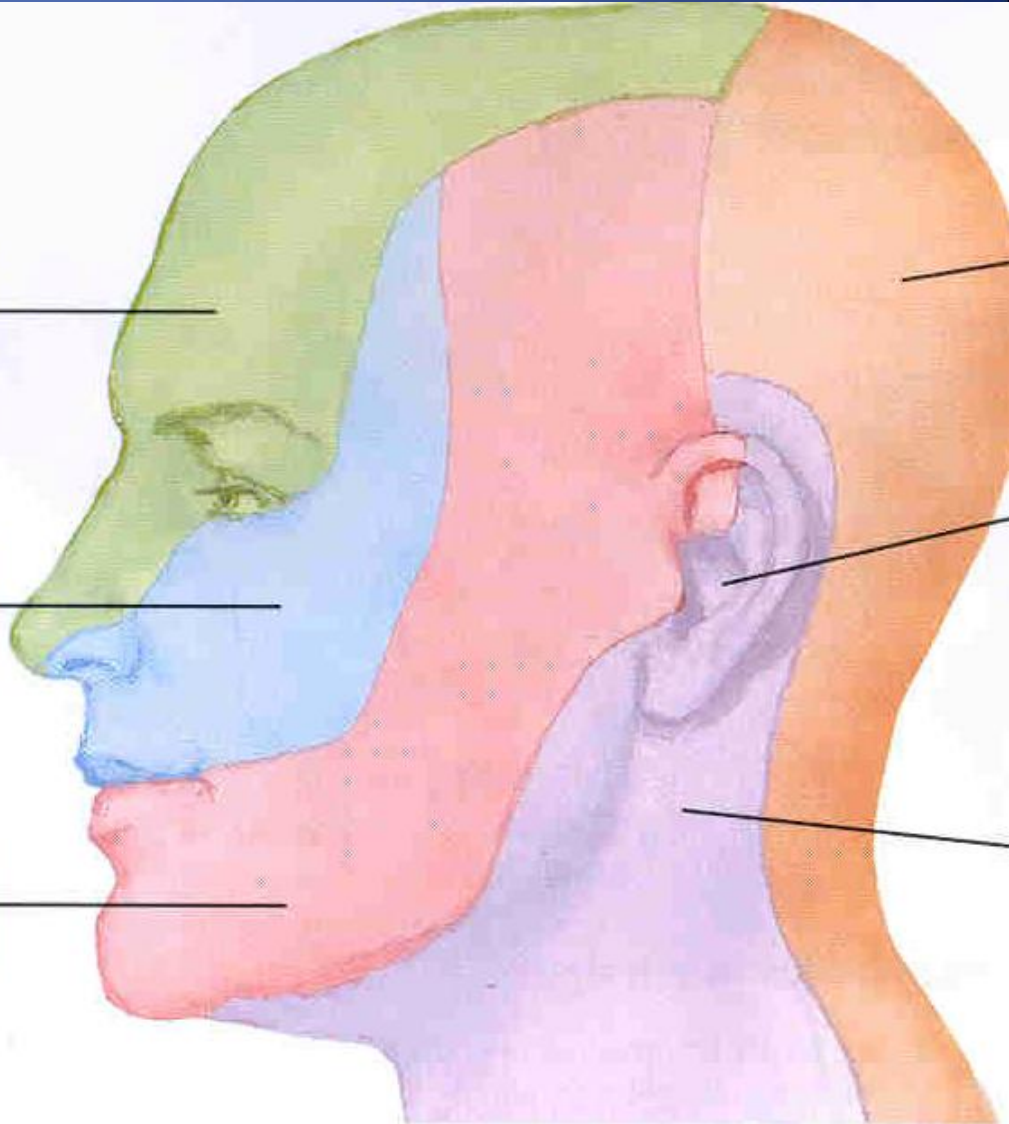
Prof. Dr. Sezgin İlgi

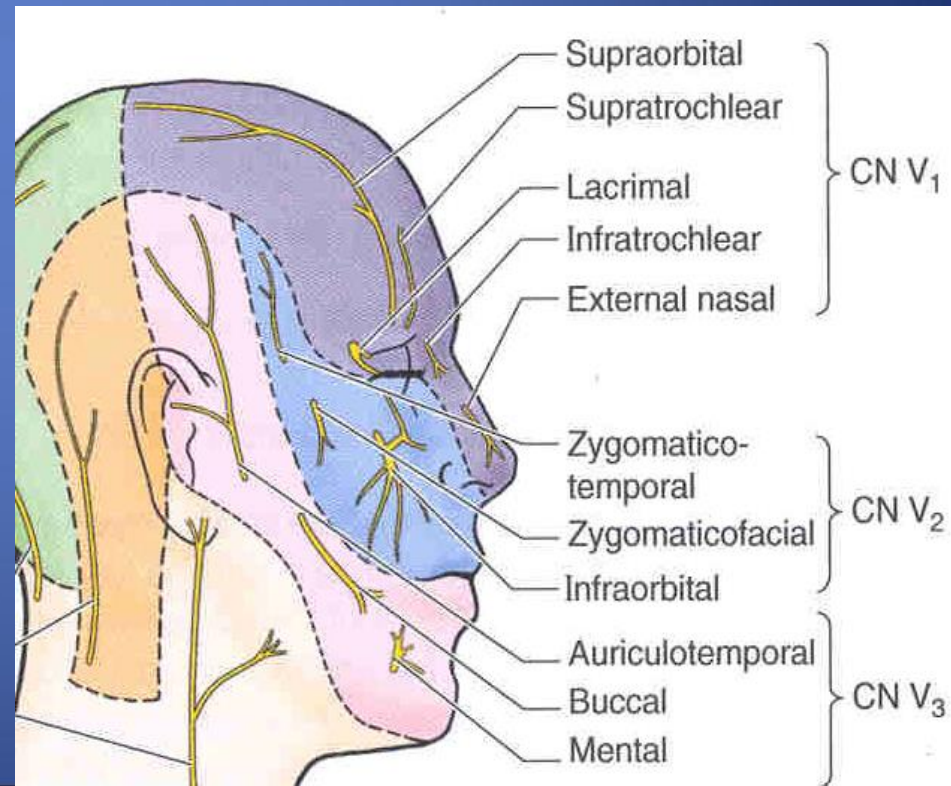
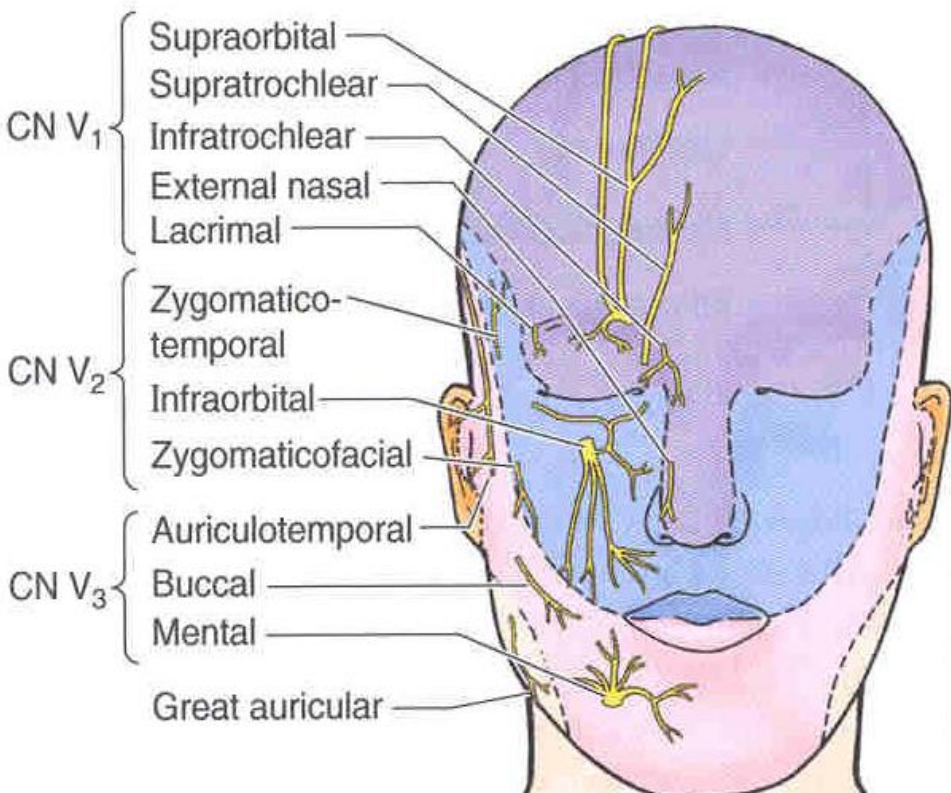
n. trigeminus  
(V)

n. ophthalmicus (V<sub>1</sub>)

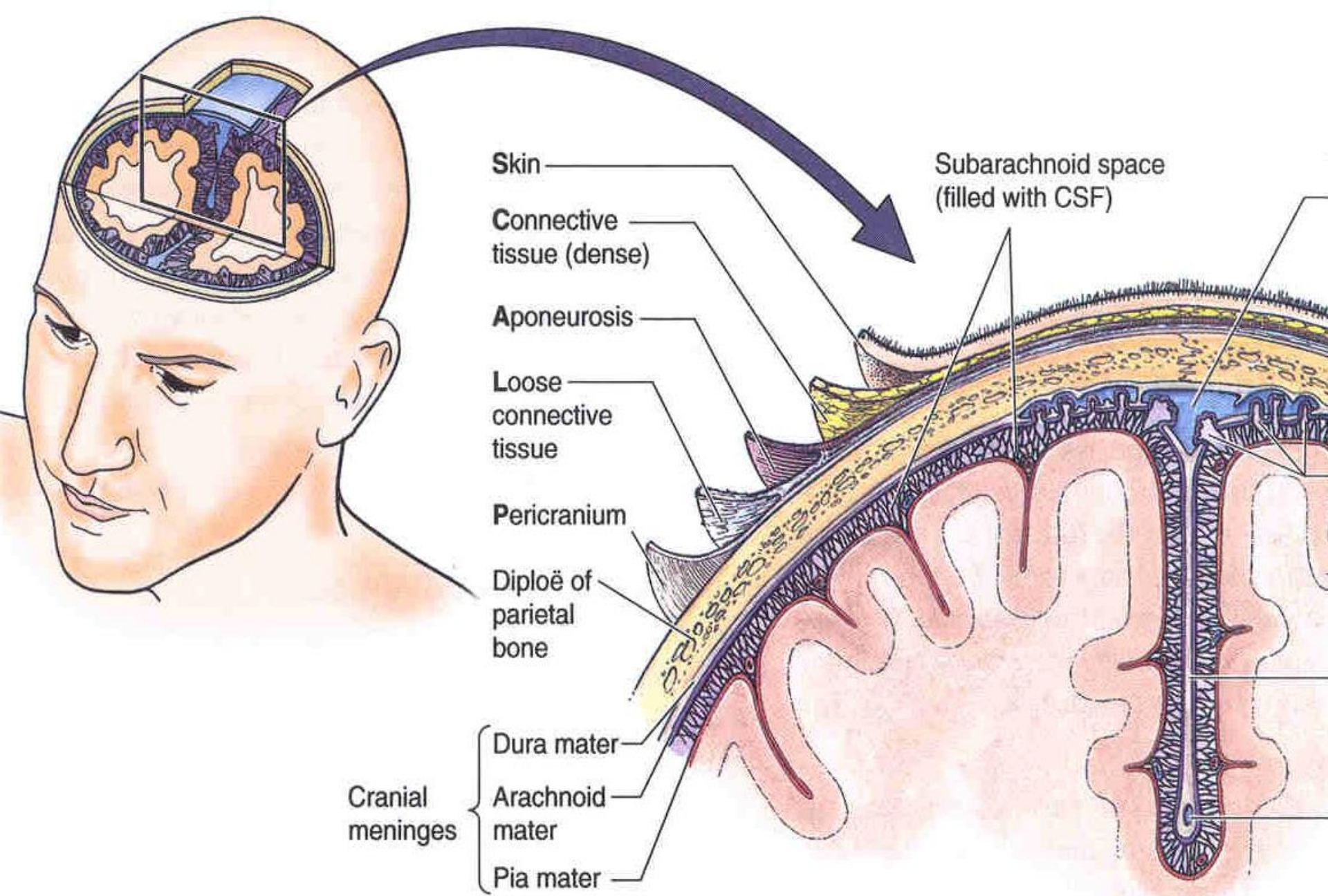
n. maxillaris (V<sub>2</sub>)

n. mandibularis (V<sub>3</sub>)









Skin

Connective tissue (dense)

Aponeurosis

Loose connective tissue

Pericranium

Diploë of parietal bone

Cranial meninges

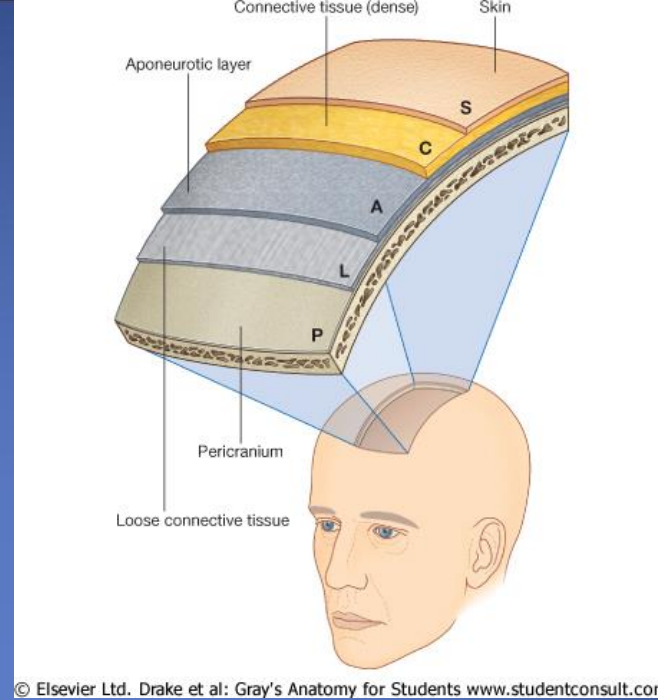
Dura mater

Arachnoid mater

Pia mater

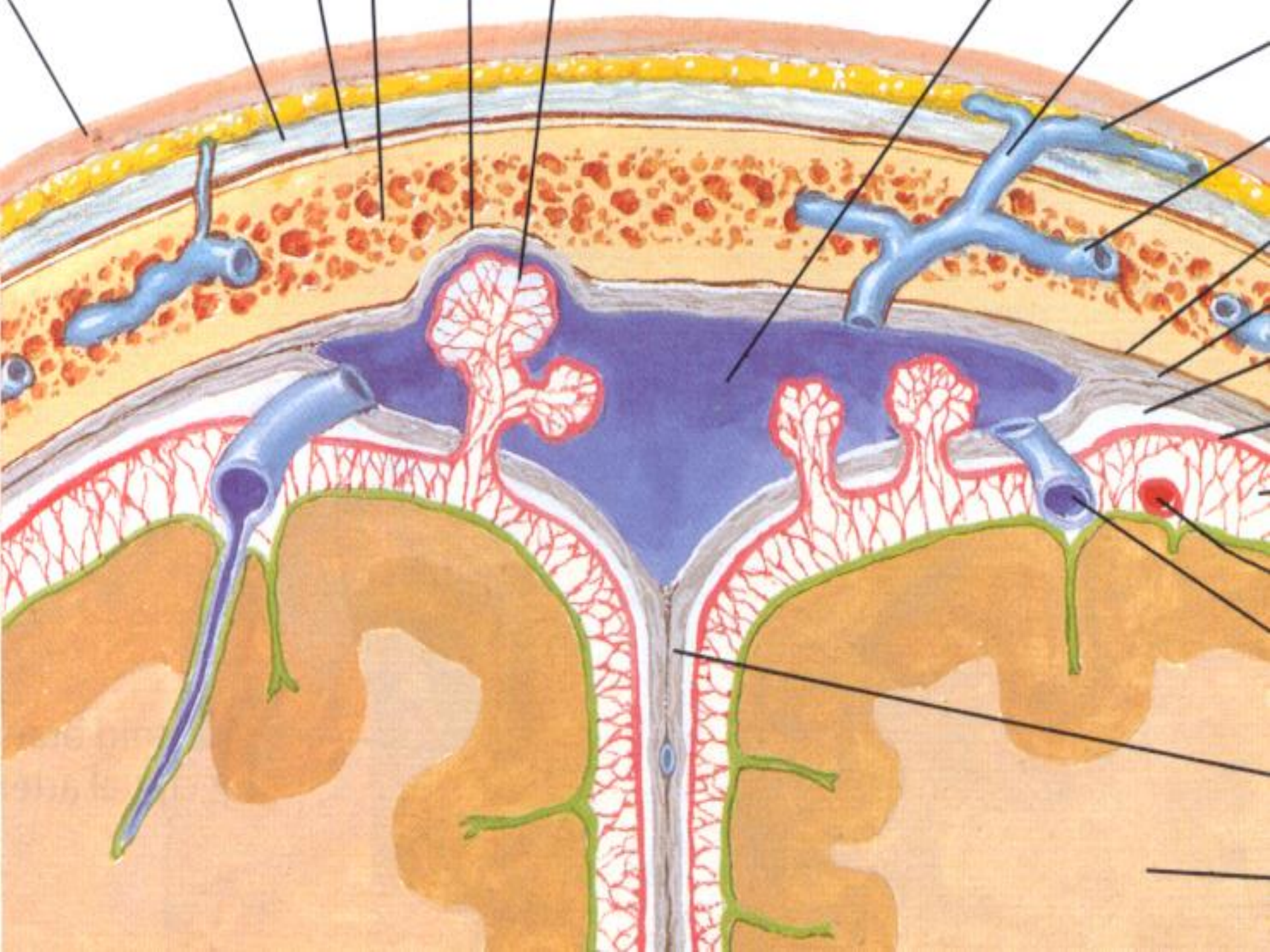
Subarachnoid space (filled with CSF)

# SCALP



- 1- **S**kin:Deri
- 2- **C**onnective tissue (subcutis): Yüzeyel fascia
- 3- **A**poneurosis (galea aponeurotica = epicranial aponeurosis)
- 4- **L**oose connective tissue: Gevşek areolar doku (vv. emissariae)
- 5- **P**ericranium: Periosteum



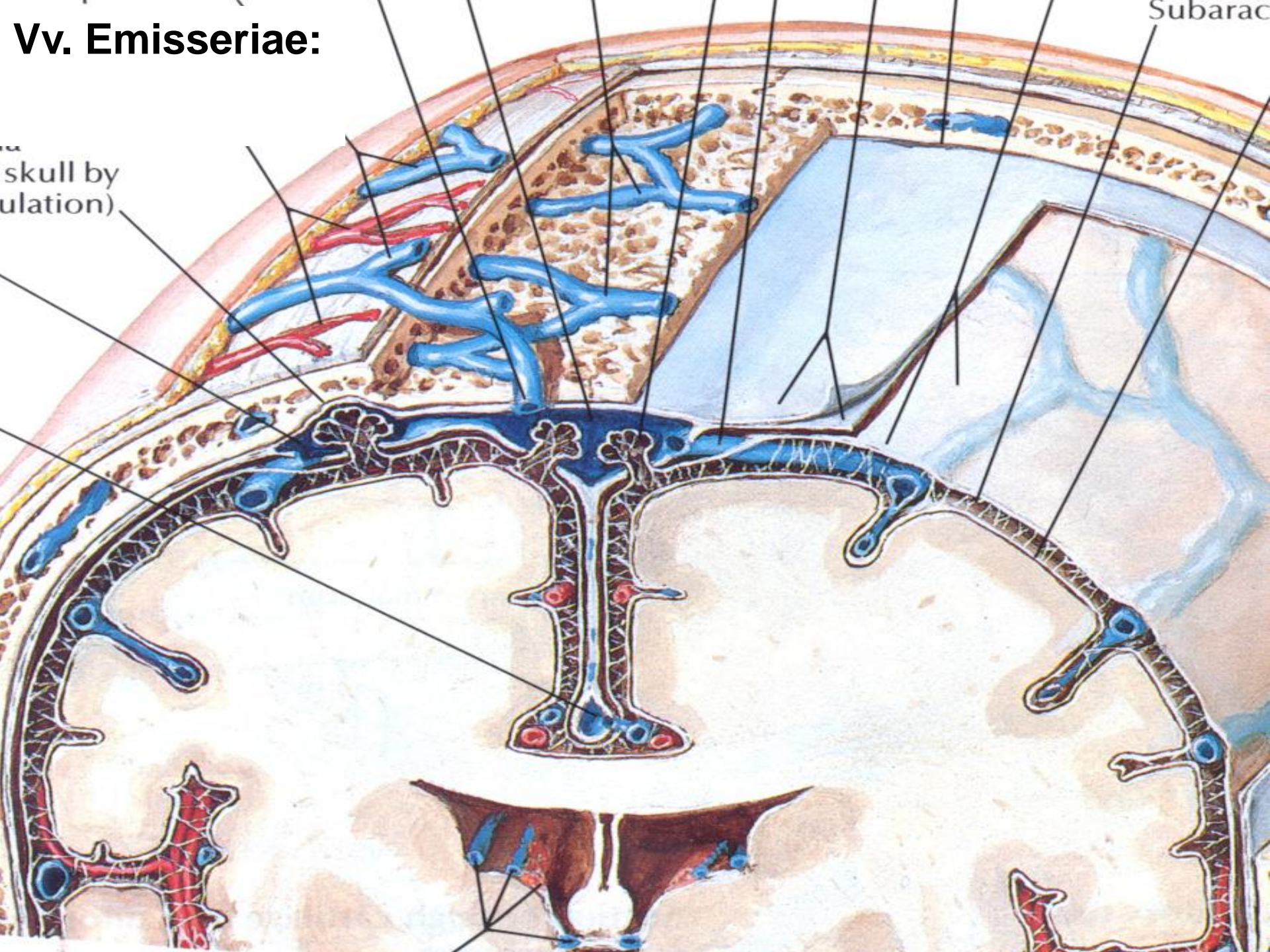




# Vv. Emissariae:

(...  
skull by  
pulsation)

Subarac

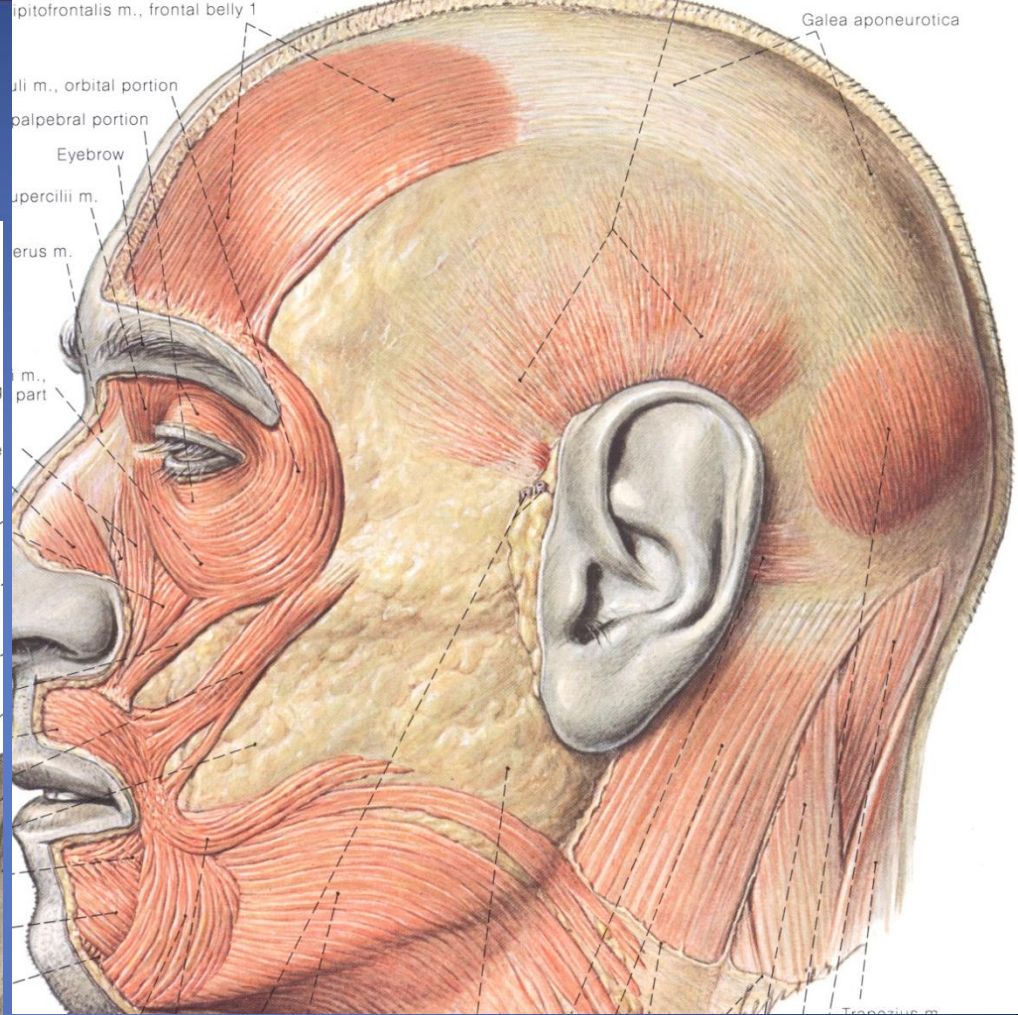
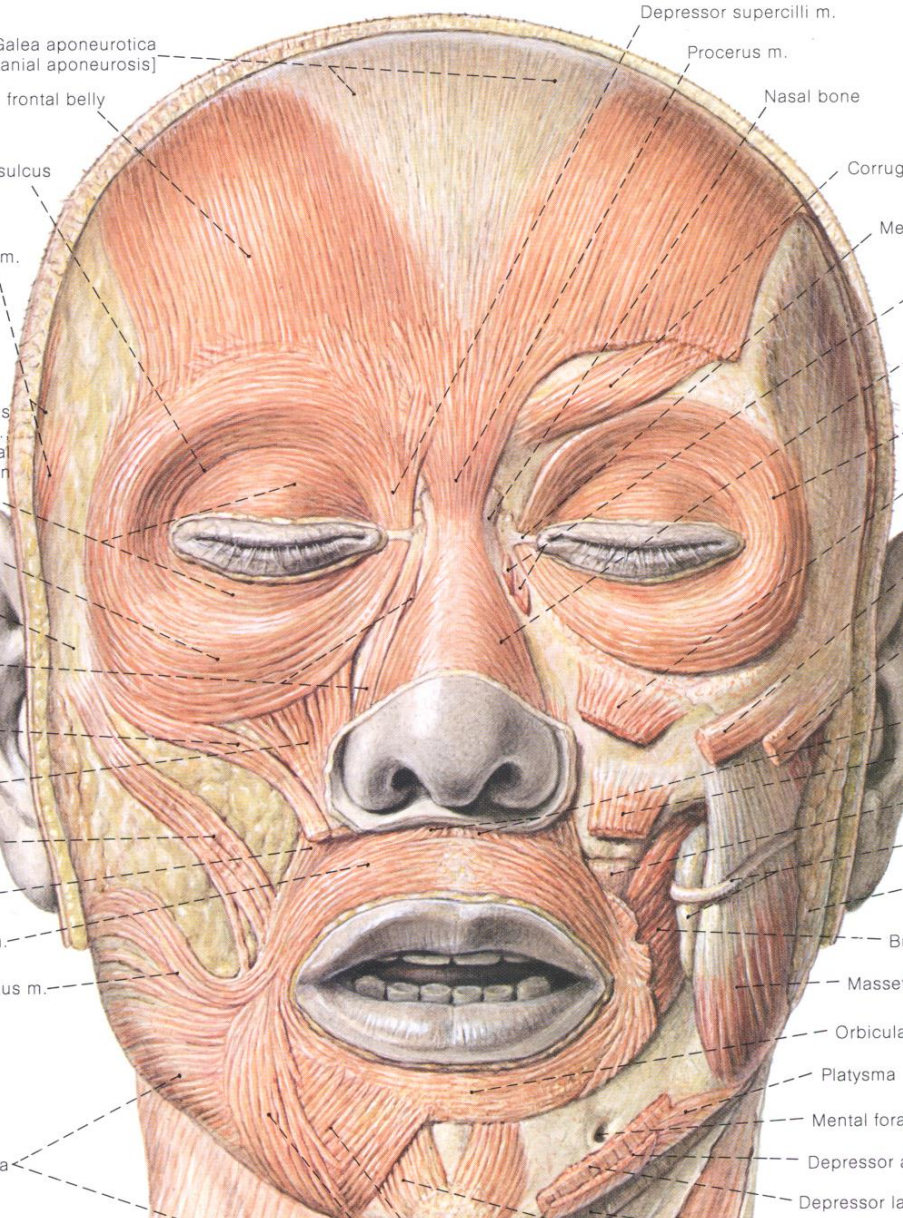


# **M. epicranius**

- **M. Occipitofrontalis**
- **M. Temporoparietalis**

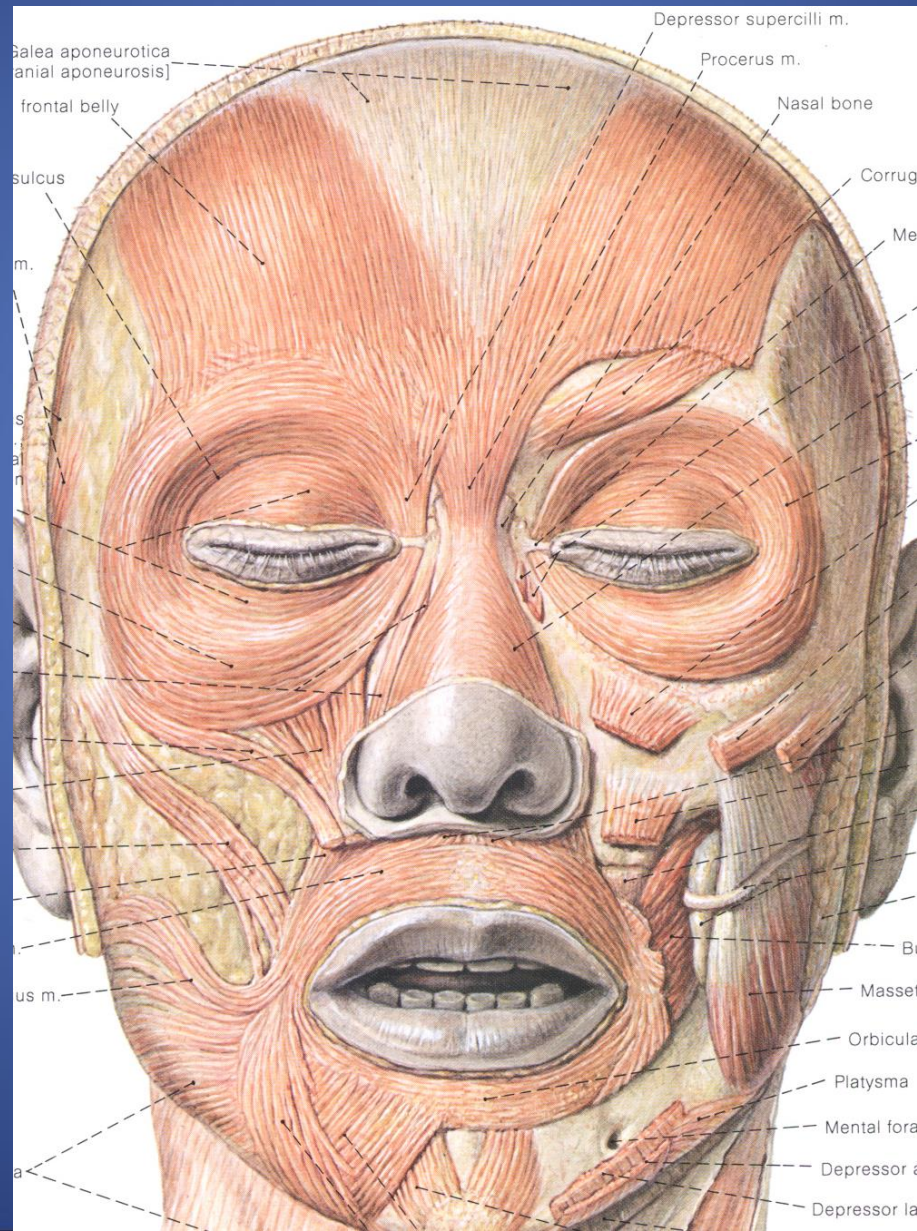


# M. Occipitofrontalis



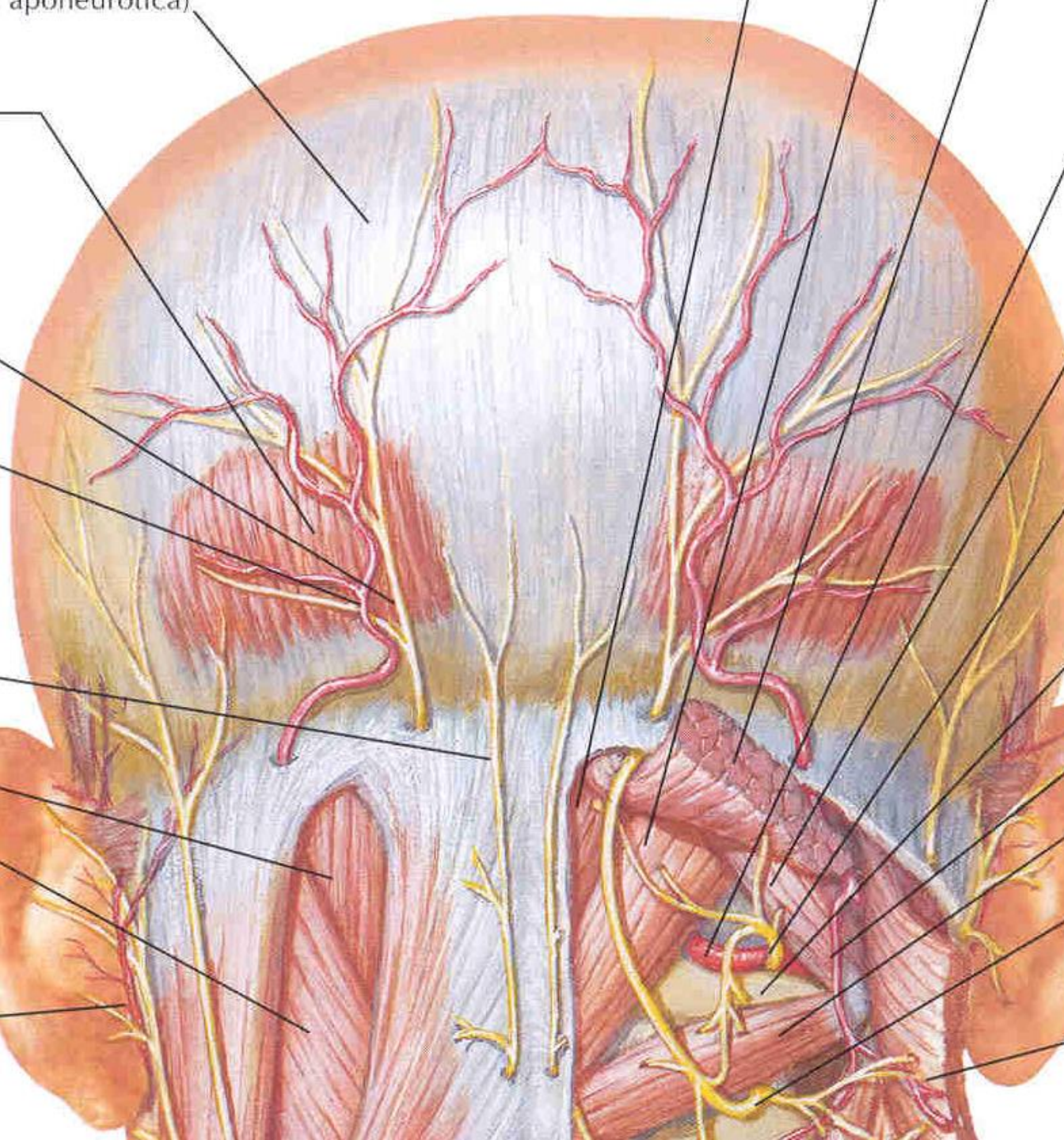


# Venter frontalis





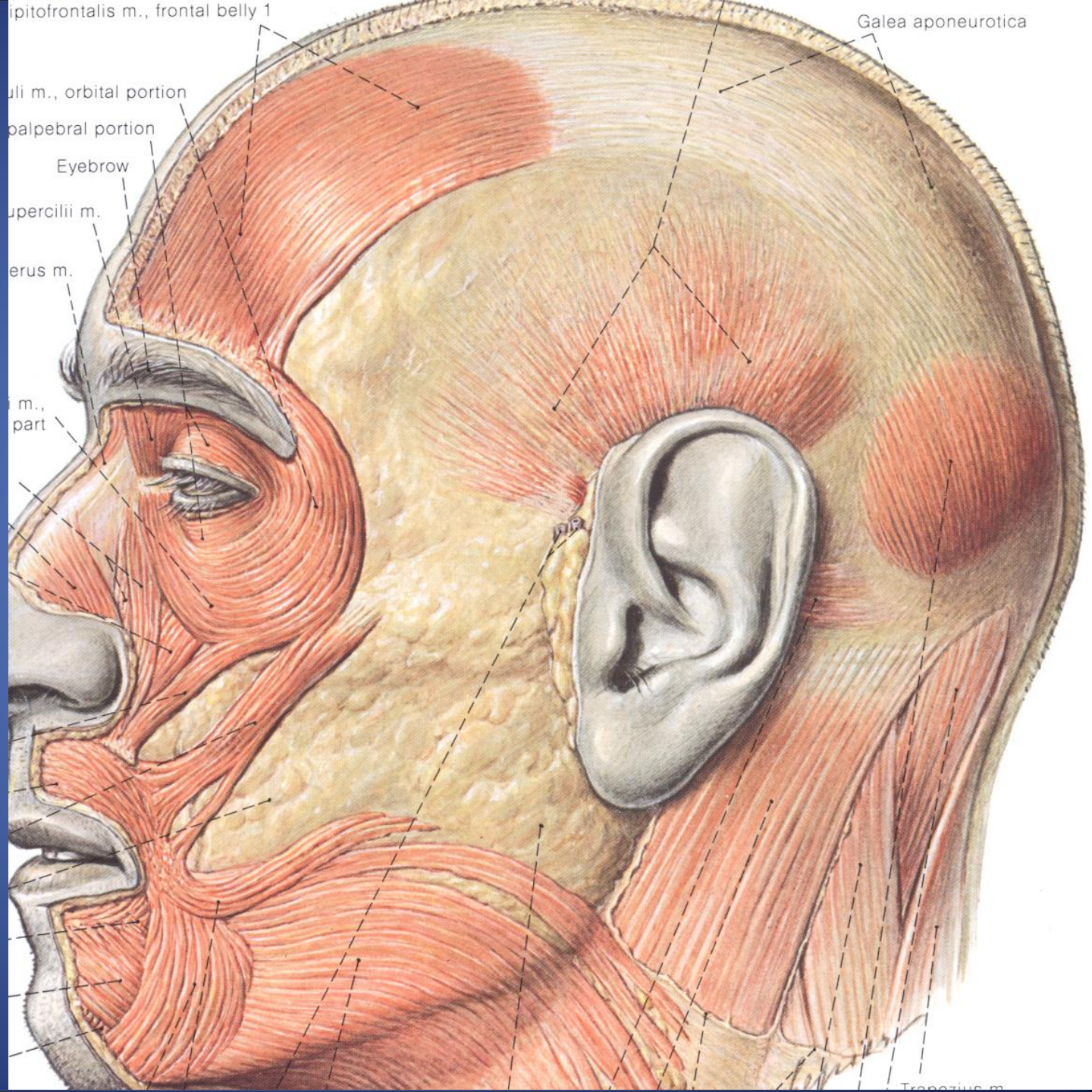
aponeurotica)



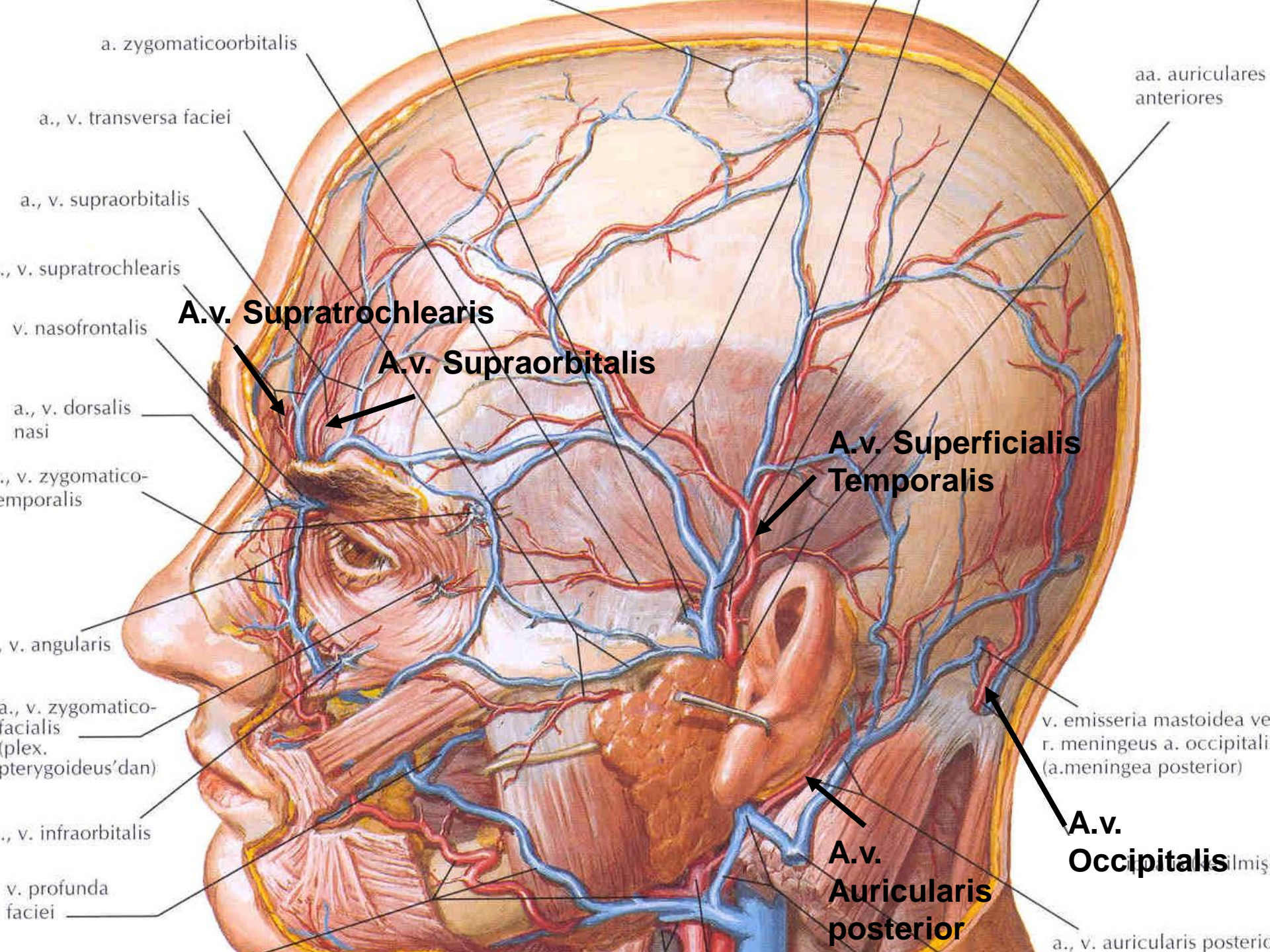
# Venter occipitalis



# M. Temporoparietalis







a. zygomaticoorbitalis

a., v. transversa faciei

a., v. supraorbitalis

a., v. supratrochlearis

**A.v. Supratrochlearis**

v. nasofrontalis

**A.v. Supraorbitalis**

a., v. dorsalis nasi

**A.v. Superficialis Temporalis**

a., v. zygomatico-temporalis

v. angularis

a., v. zygomatico-facialis (plex. pterygoideus'dan)

a., v. infraorbitalis

v. profunda faciei

aa. auriculares anteriores

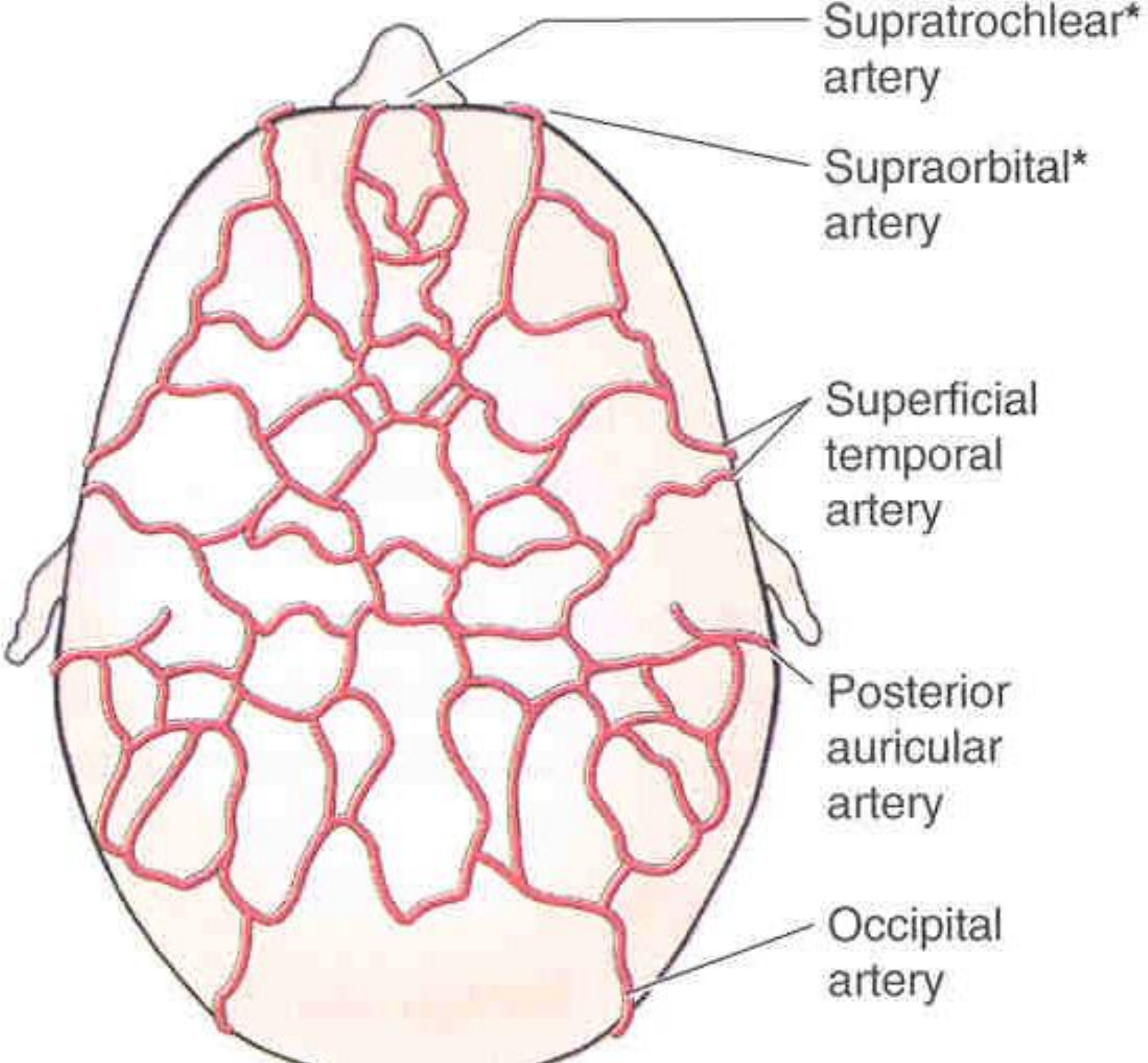
v. emissaria mastoidea ve r. meningeus a. occipitali (a.meningea posterior)

**A.v. Occipitalis**

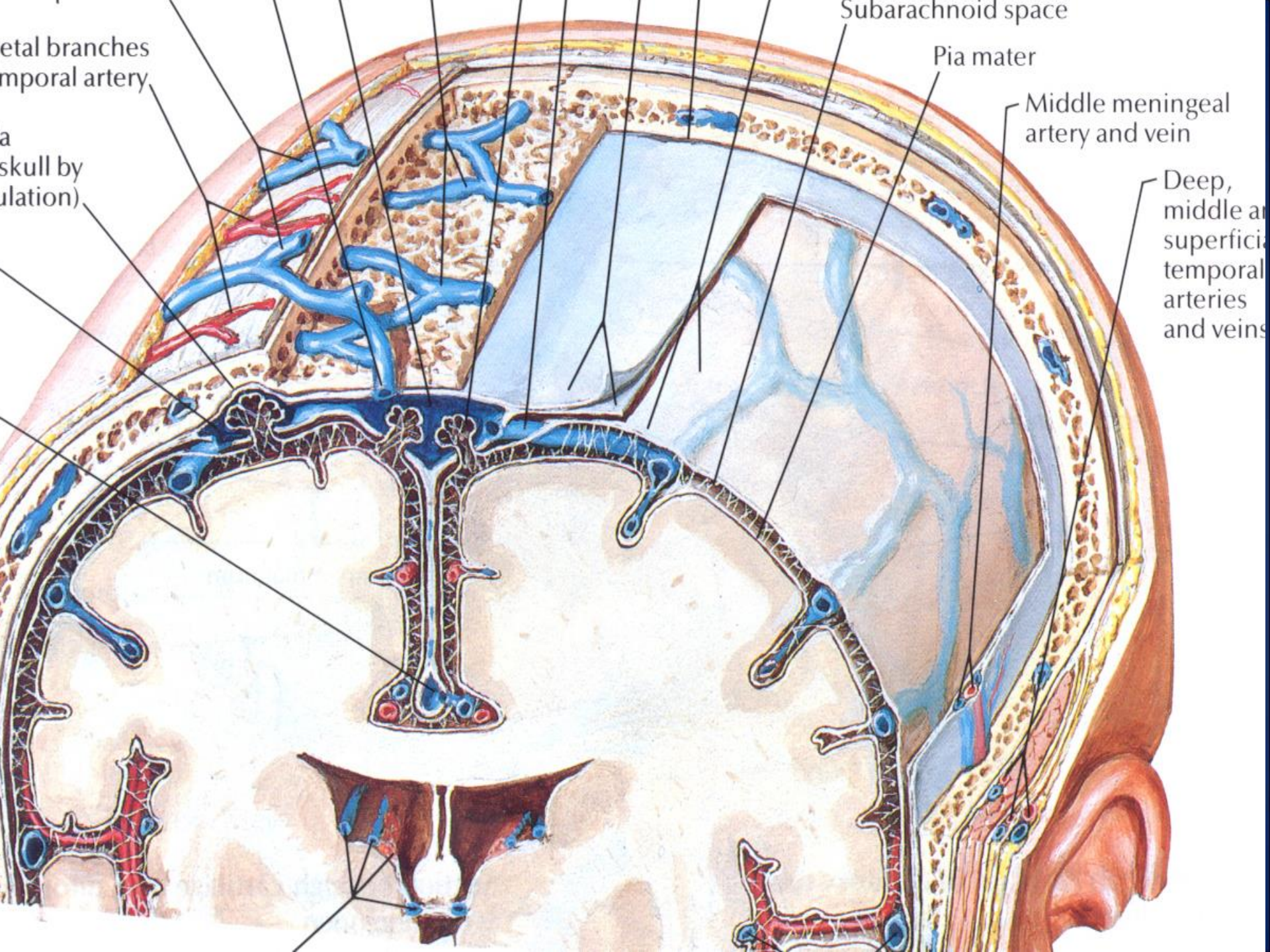
**A.v. Auricularis posterior**

a., v. auricularis posterior









Subarachnoid space

Pia mater

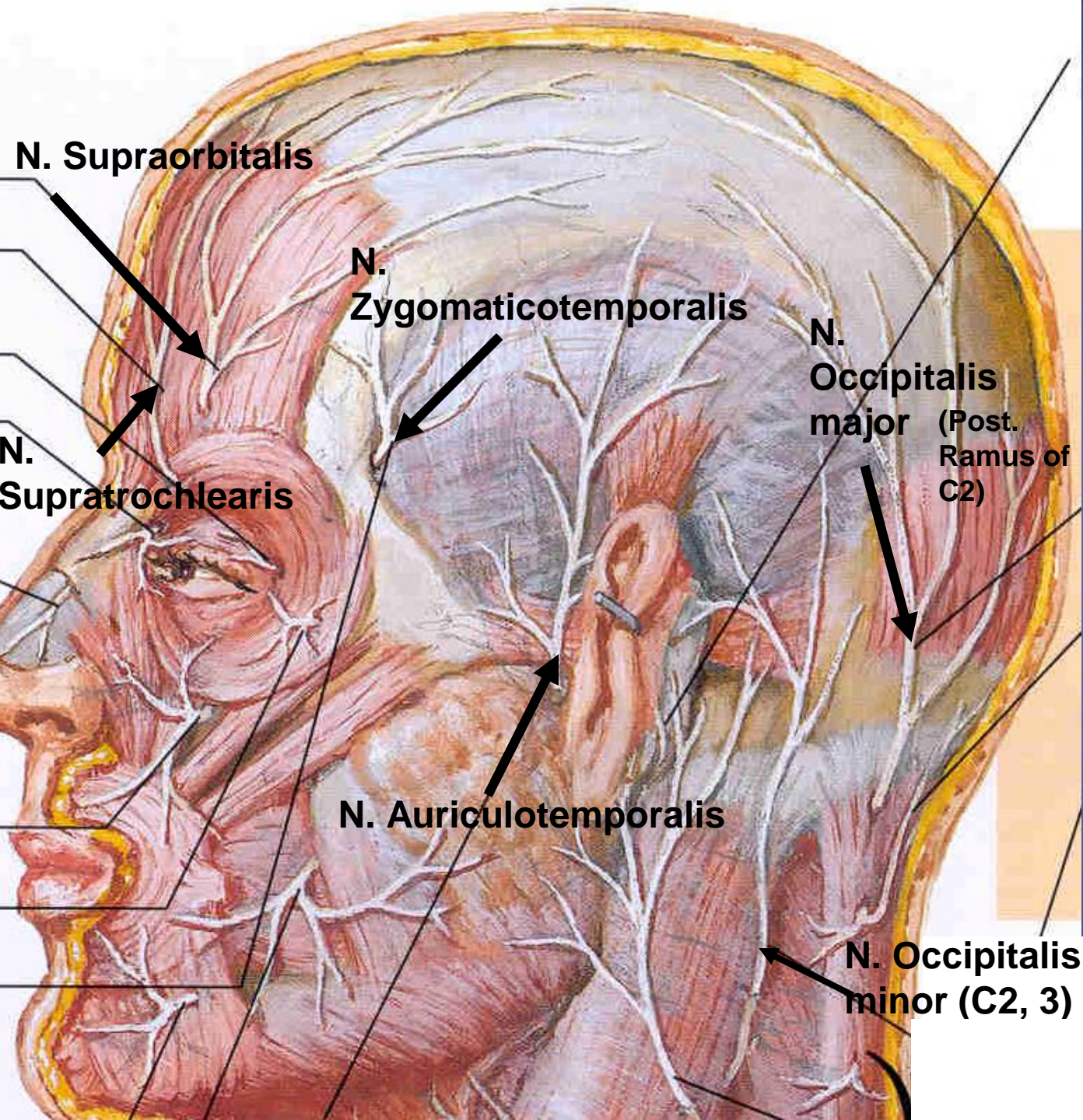
Middle meningeal artery and vein

Deep, middle and superficial temporal arteries and veins

Metal branches of temporal artery

(skull by palpation)





**N. Supraorbitalis**

**N. Zygomaticotemporalis**

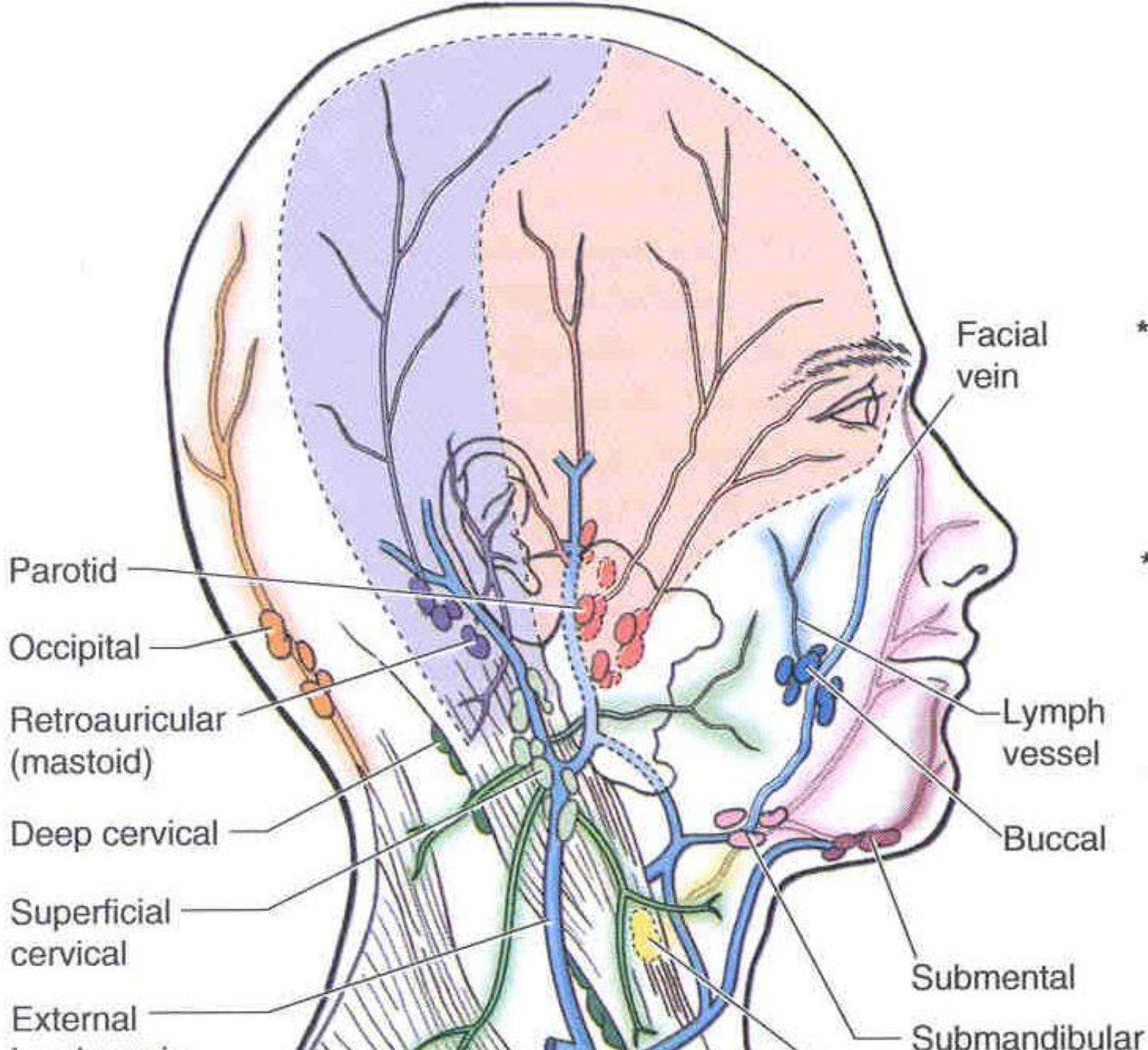
**N. Occipitalis major (Post. Ramus of C2)**

**N. Supratrochlearis**

**N. Auriculotemporalis**

**N. Occipitalis minor (C2, 3)**



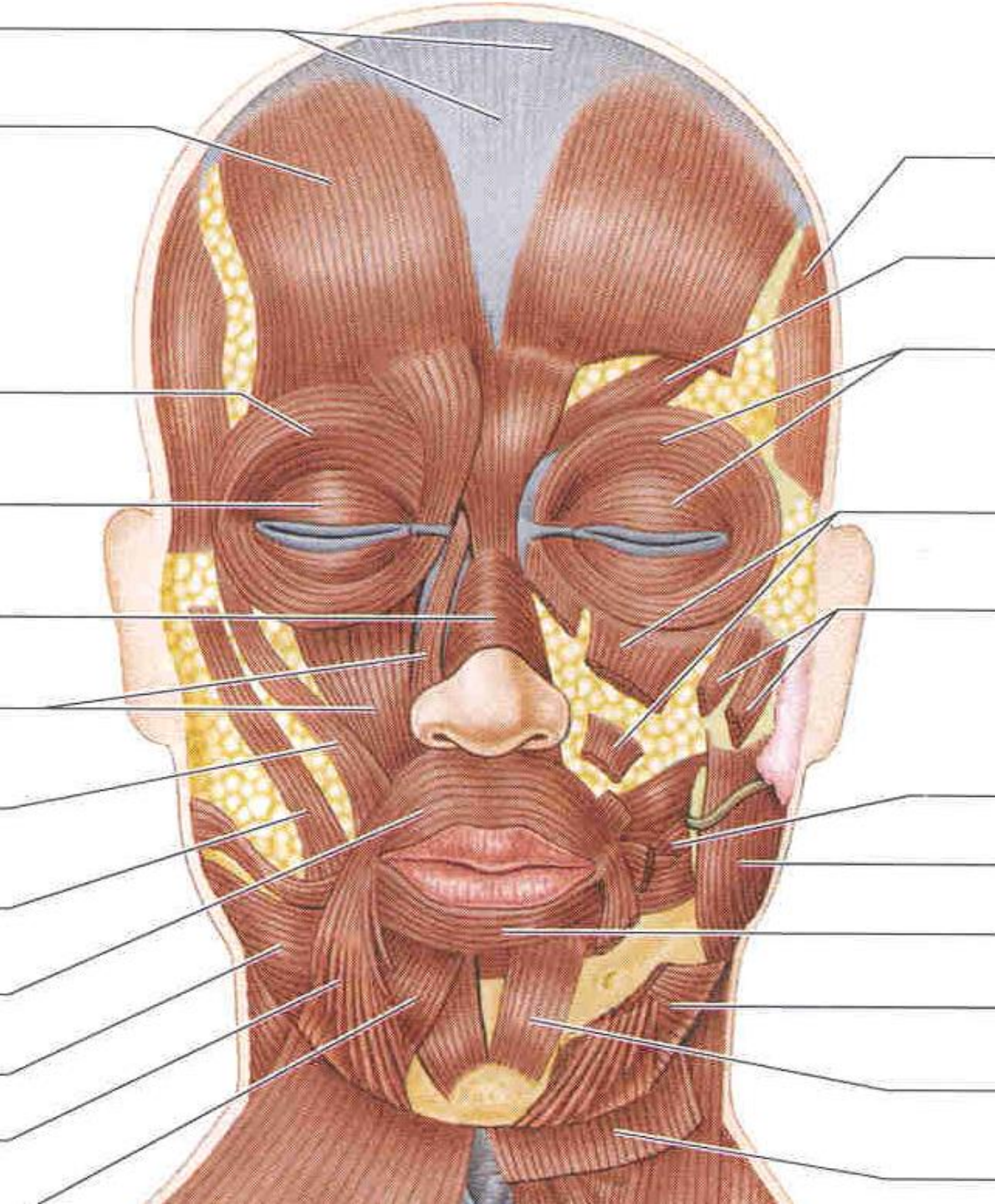


# Yüz Kasları (Mimik Kasları)

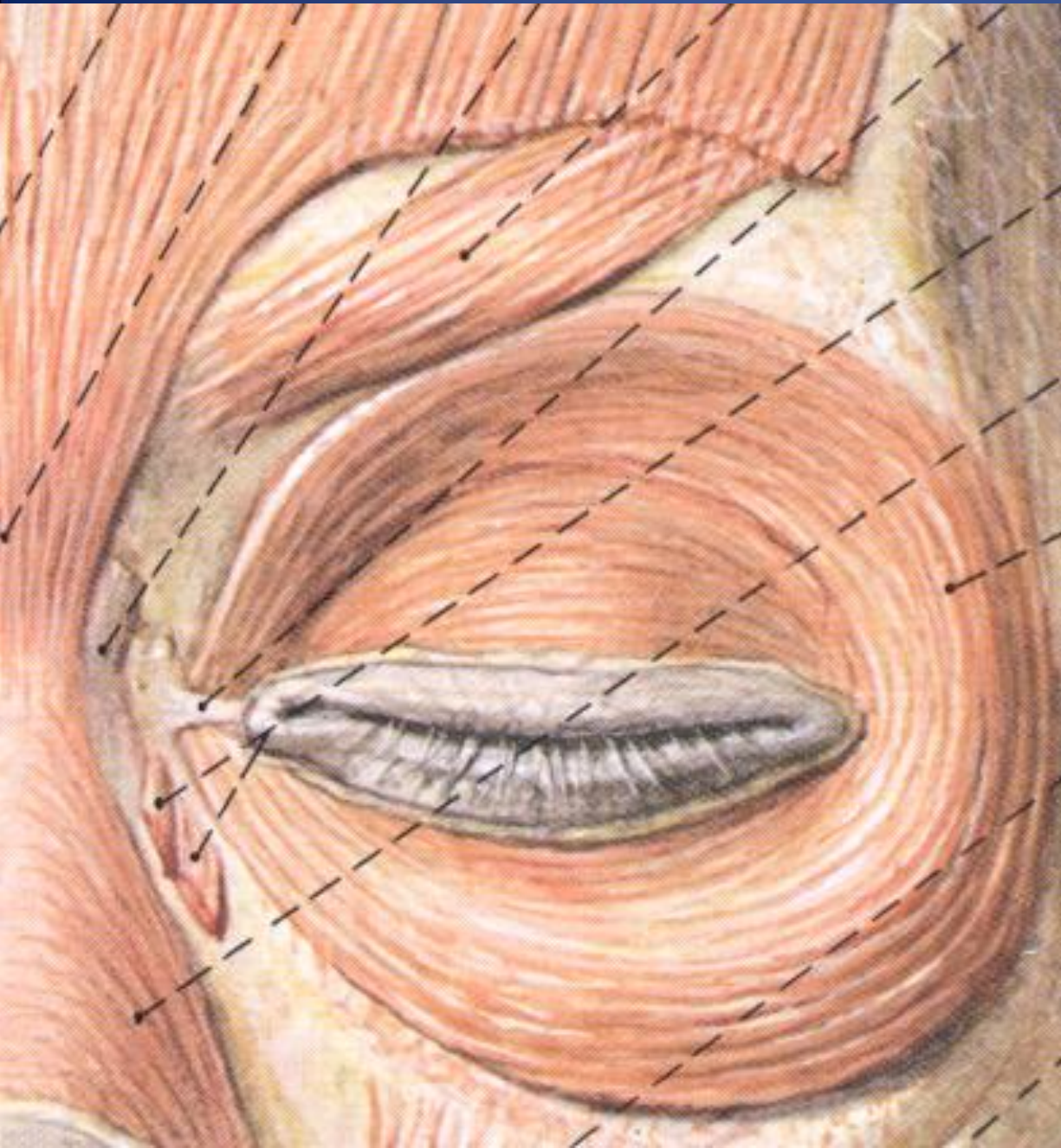
1- Göz çevresi

2- Burun Çevresi

3- Ağız çevresi





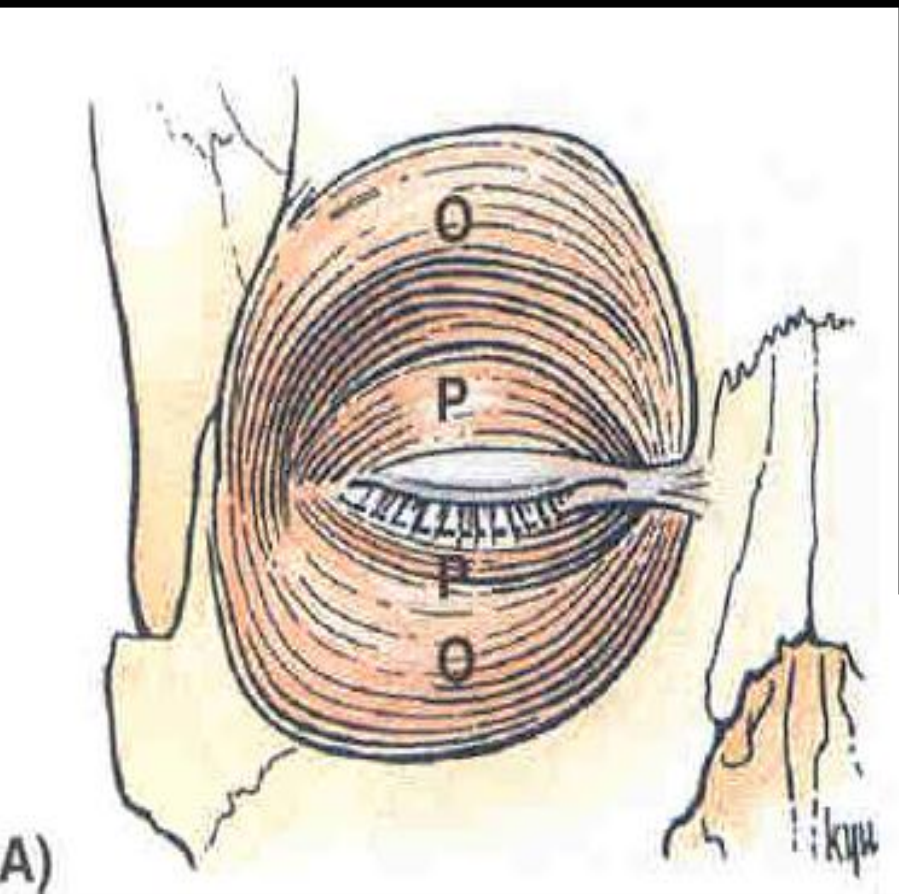
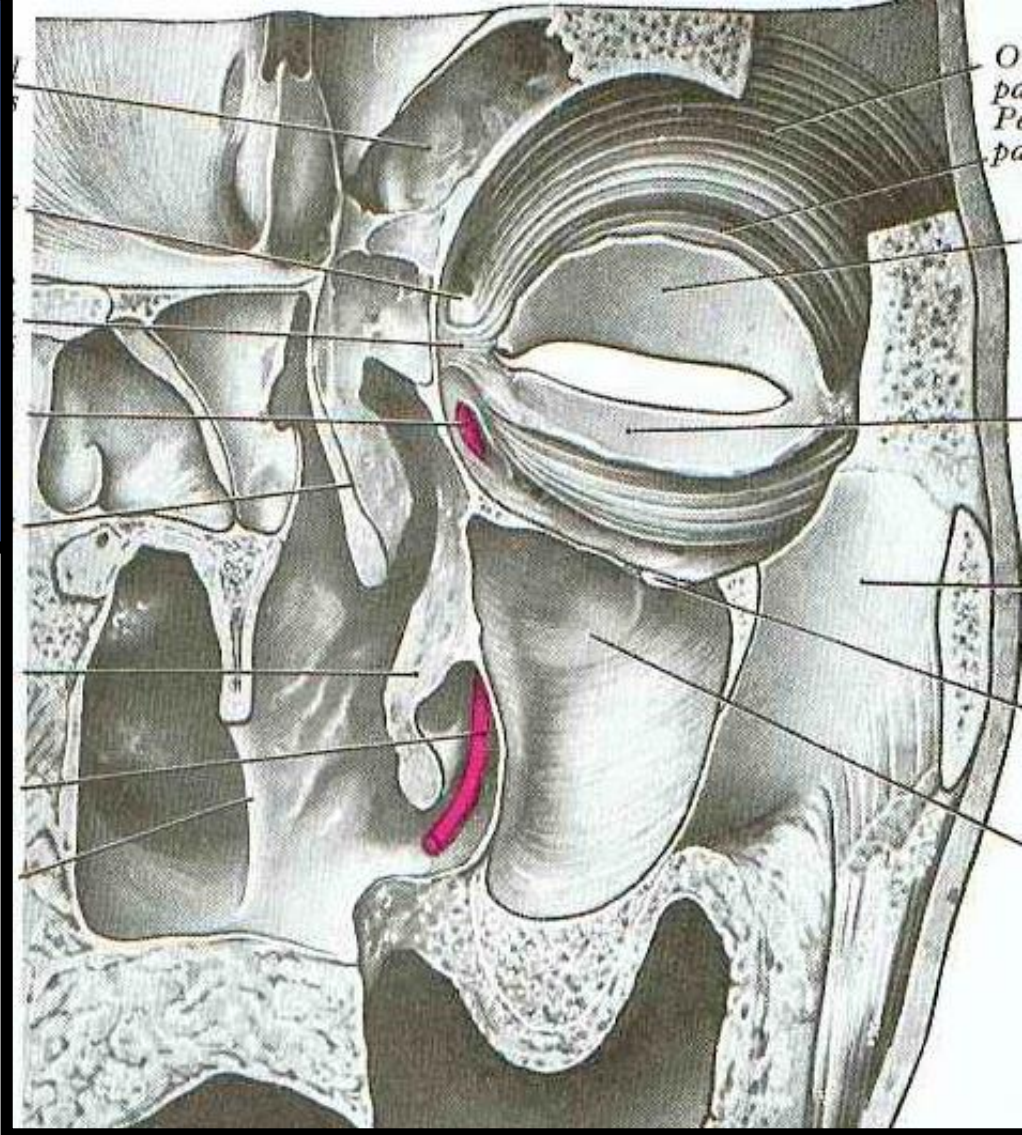


# Göz Çevresi Kaslar

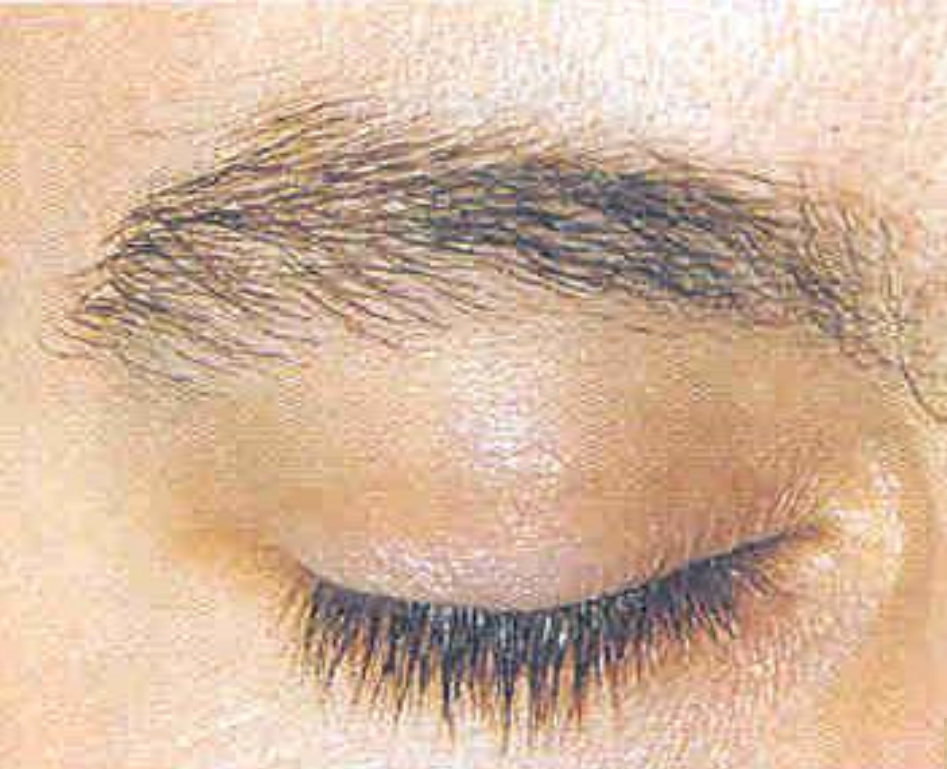- 1- M. Orbicularis oculi
- 2- M. Corrugator supercilii
- 3- M. Depresor supercilii



# M. Orbicularis oculi

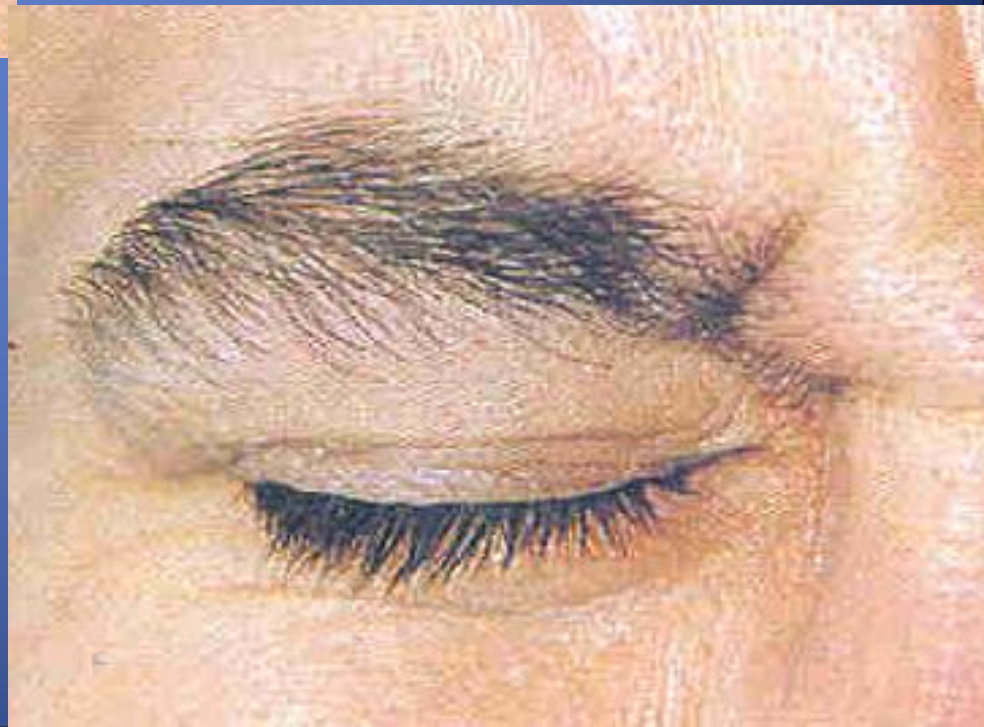





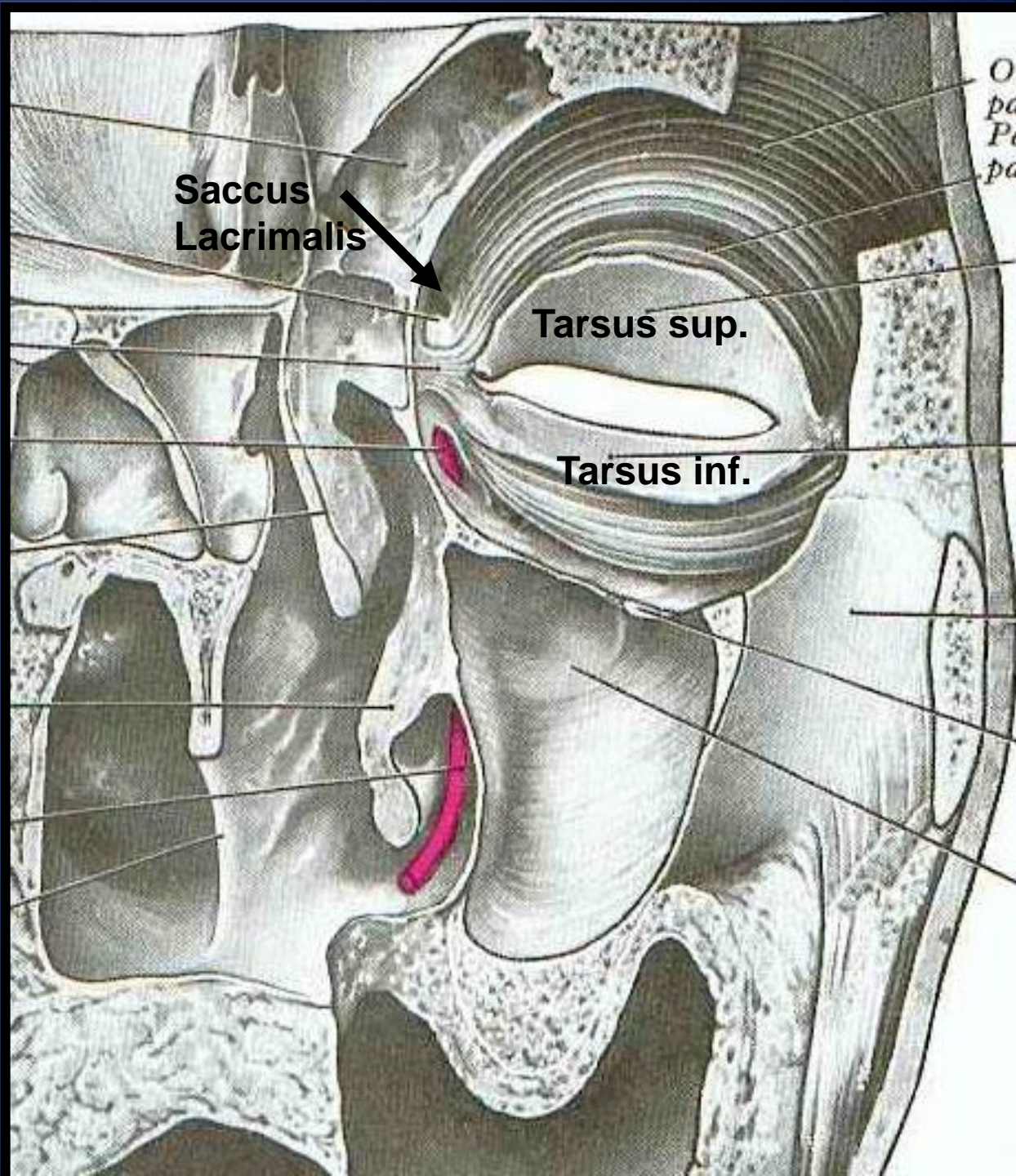
**Pars Orbitalis**

**Pars Palpebralis**



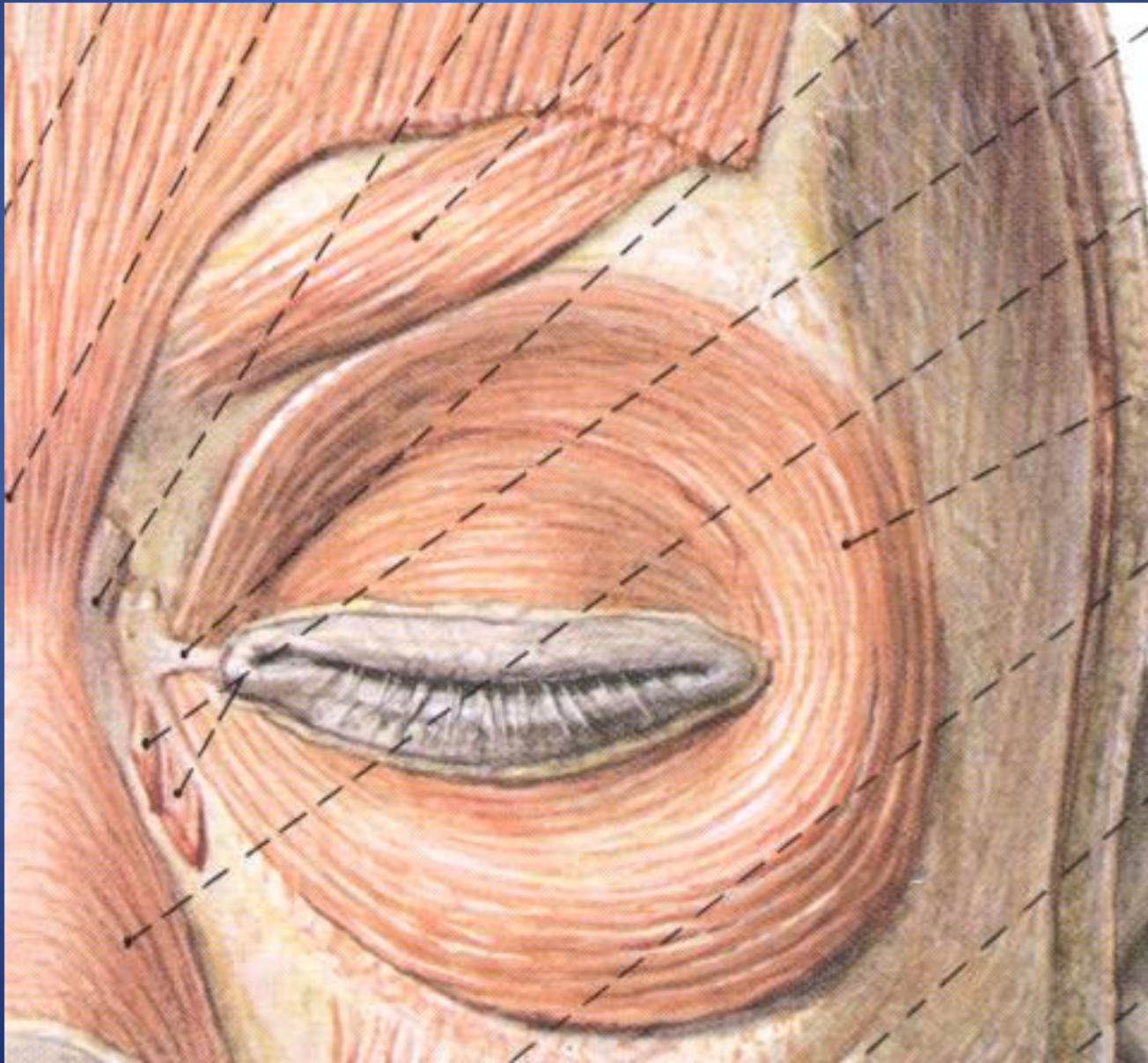


# Pars Lacrimalis



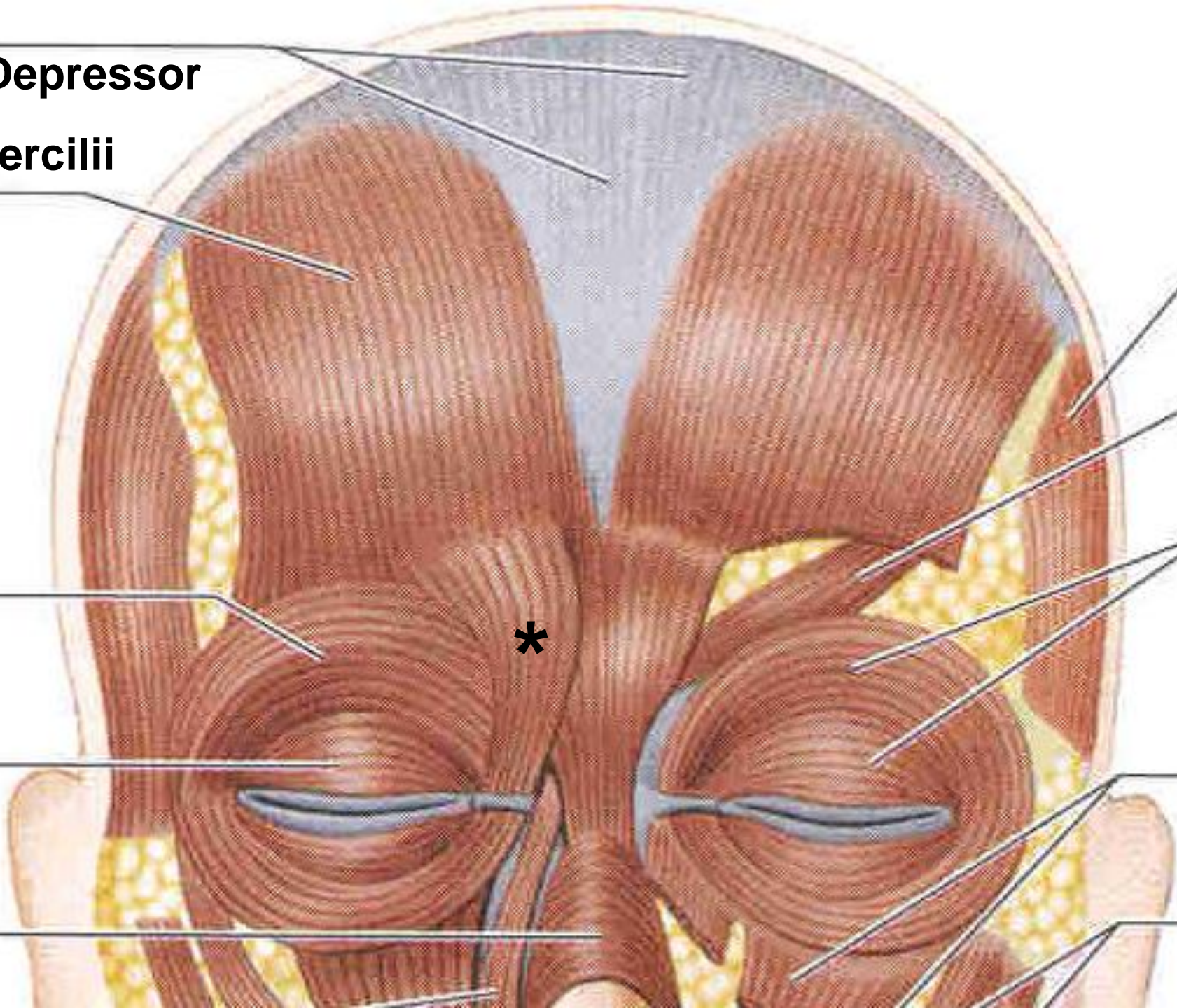


# M. Corrugator supercilii





**M. Depressor  
supercilii**



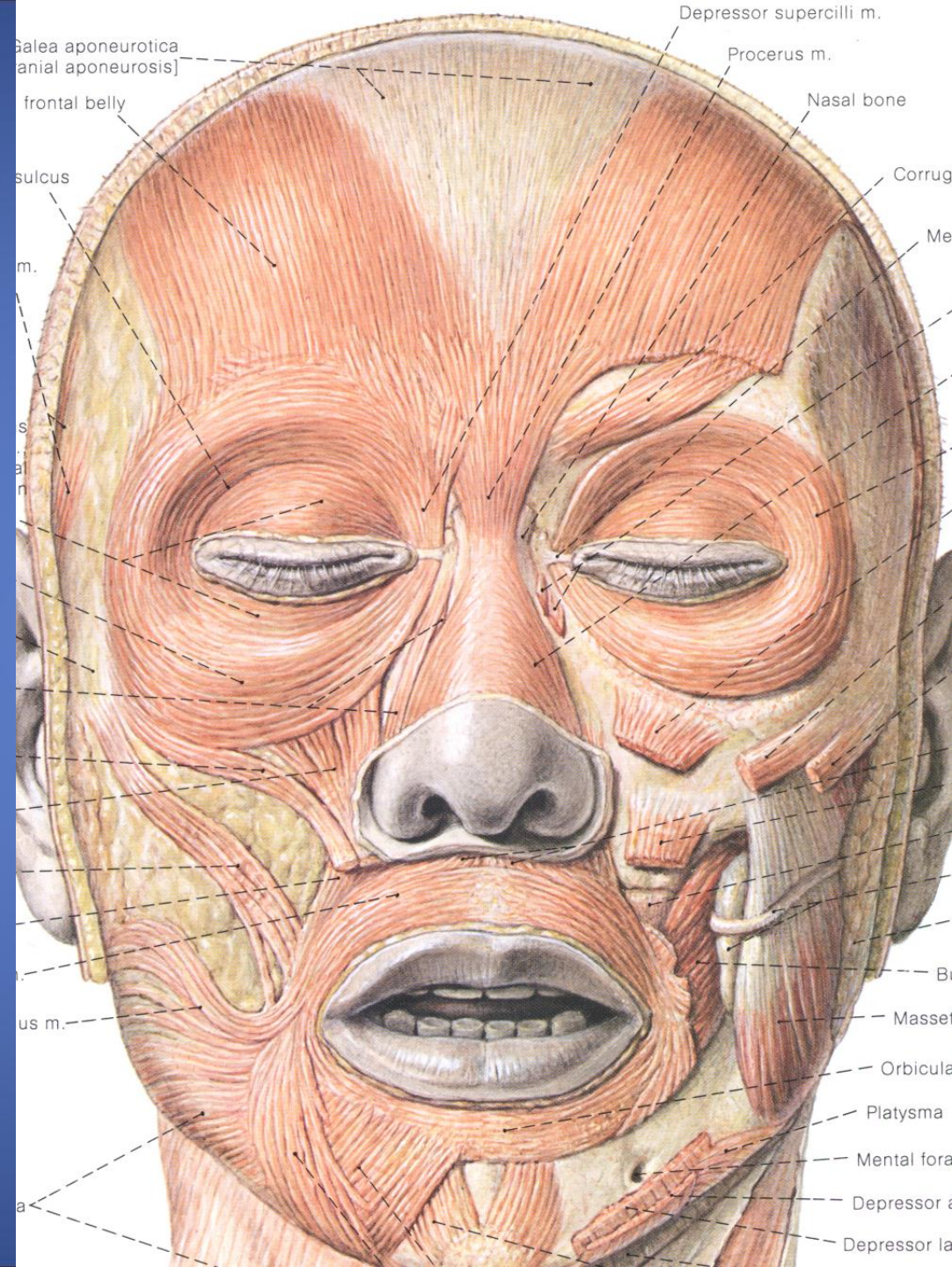


# Burun Kasları

1- M. Nasalis

2- M. Procerus

3- M. Depressor septi

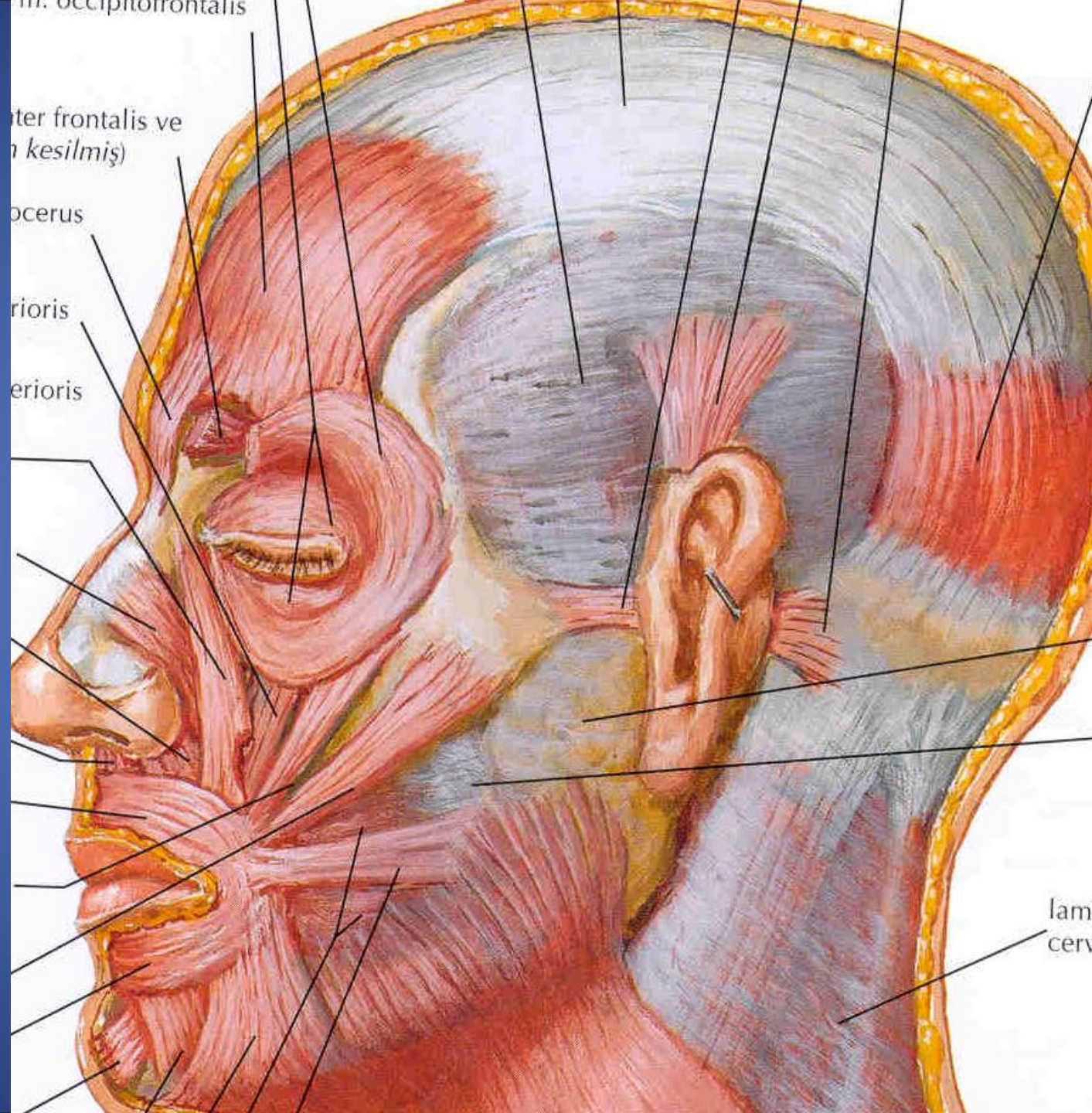




# M. Nasalis

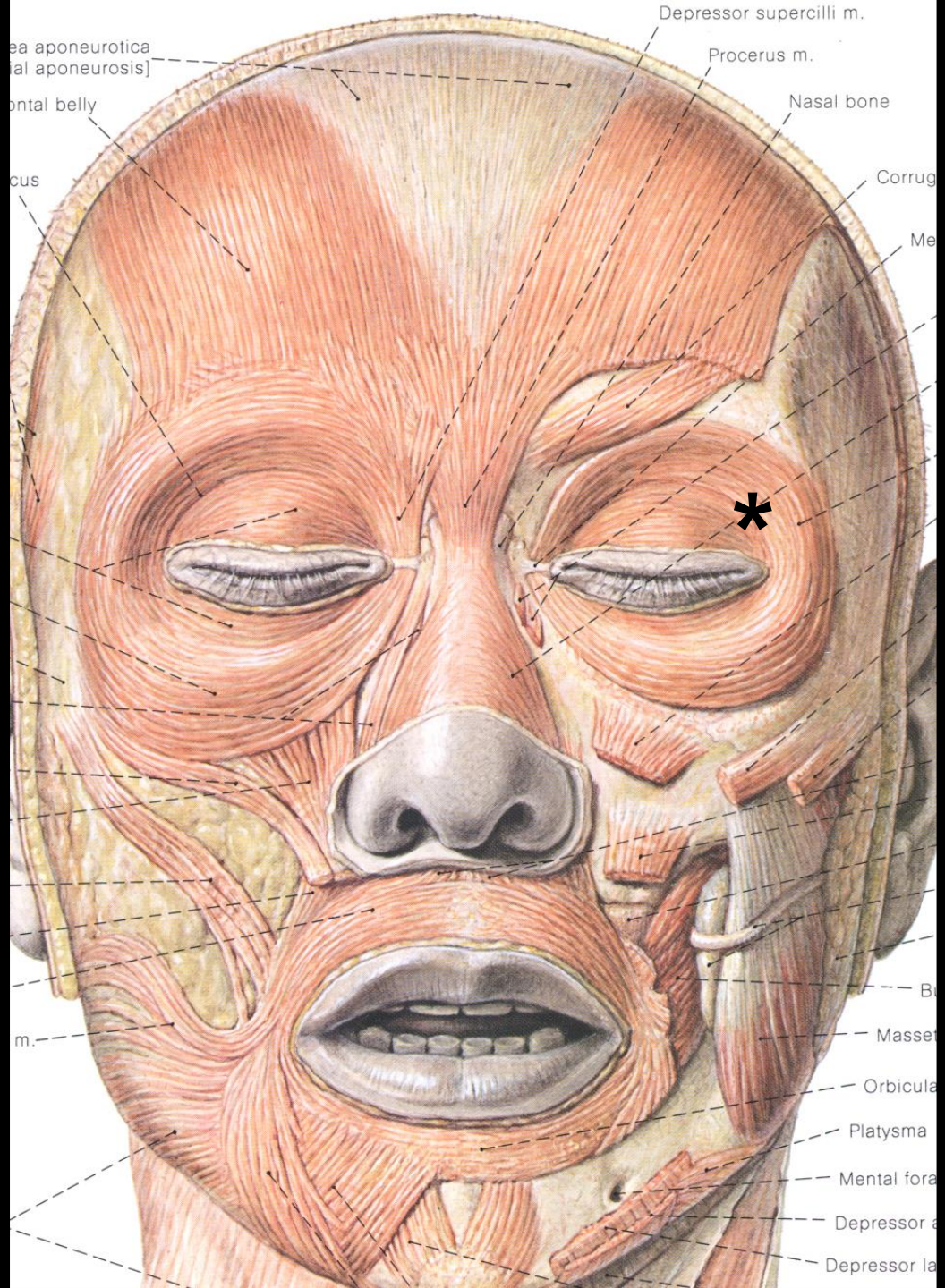
Pars transversa

Pars alaris



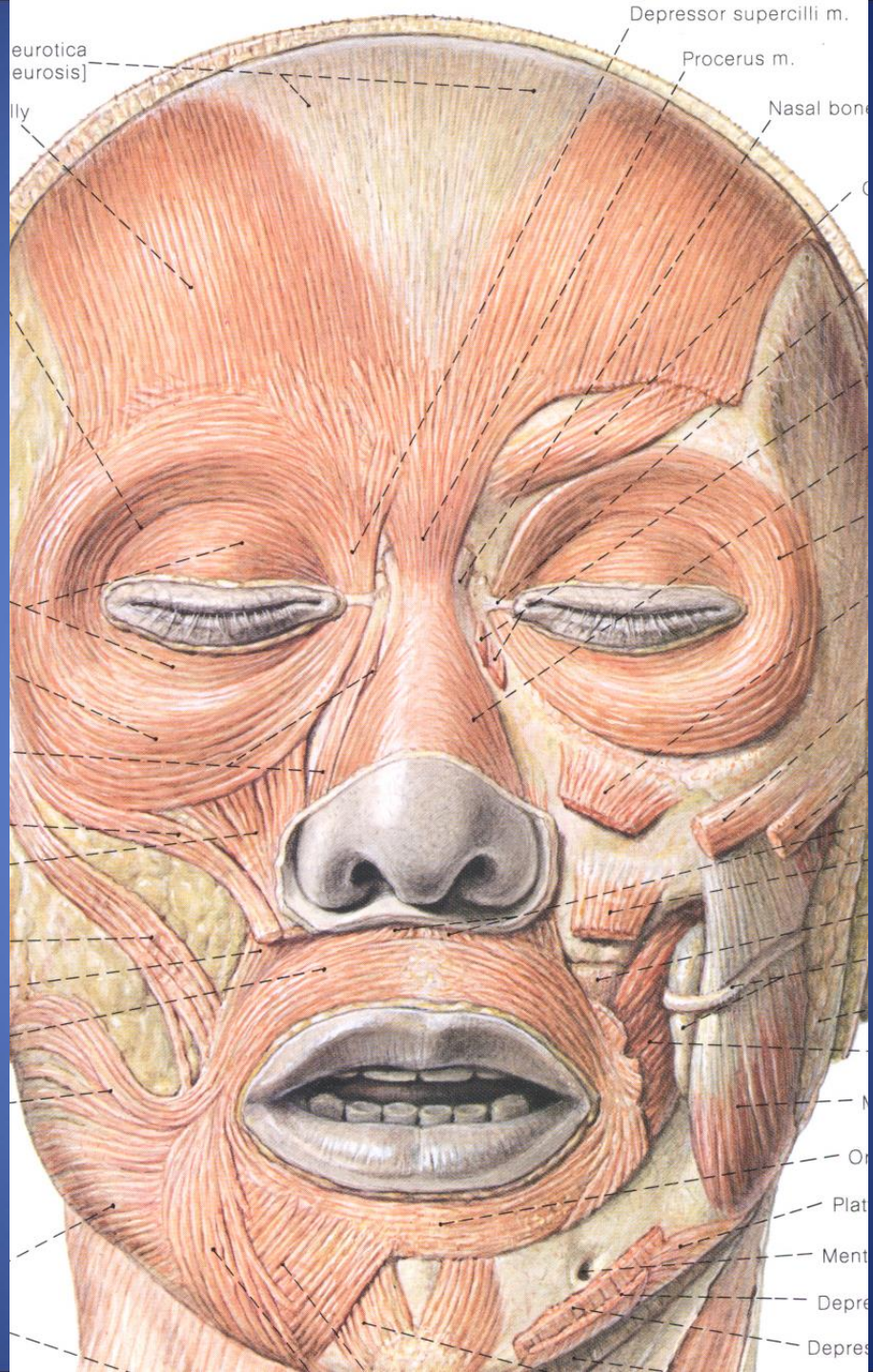


# M. Procerus



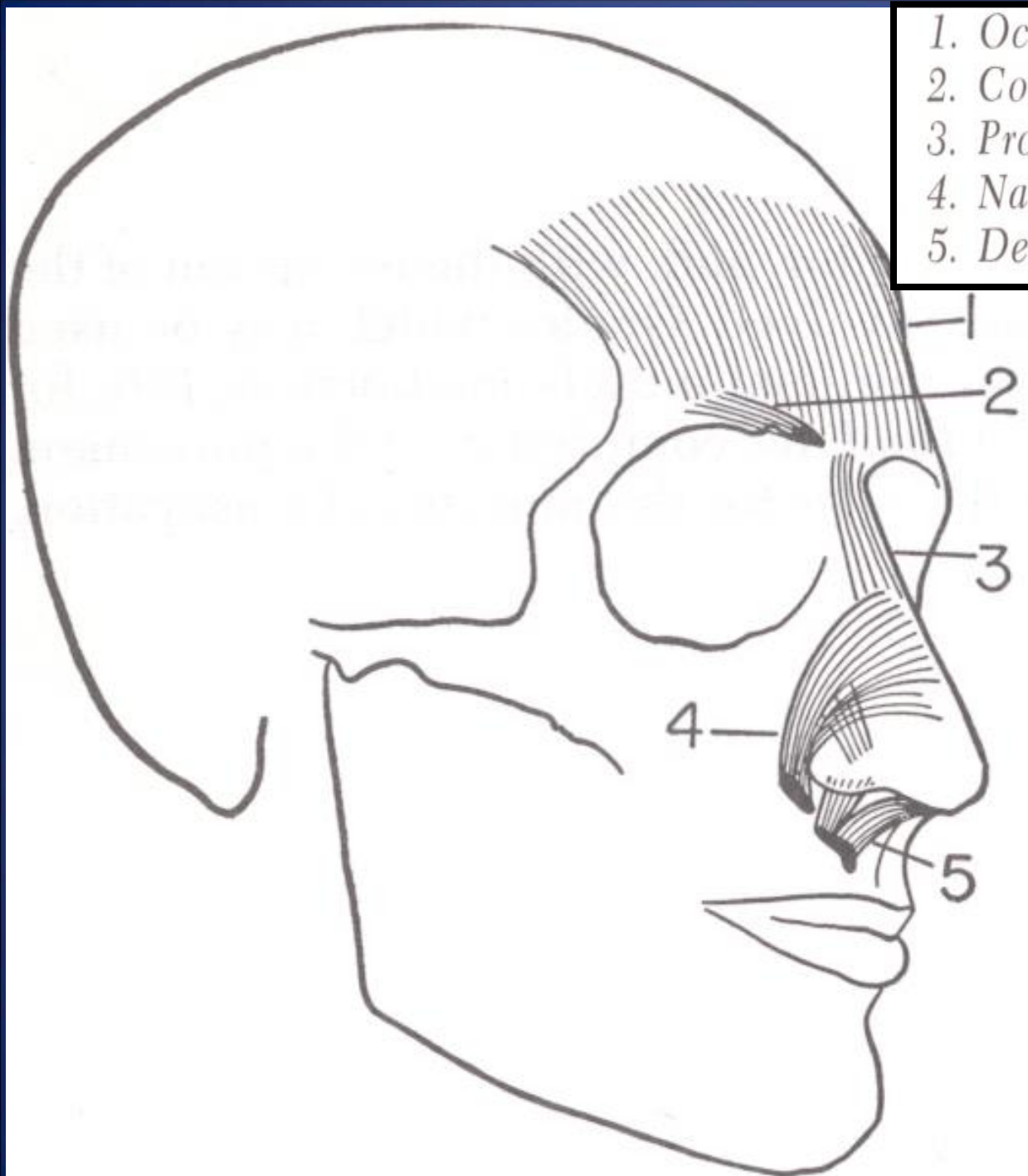


# M. Depressor septi





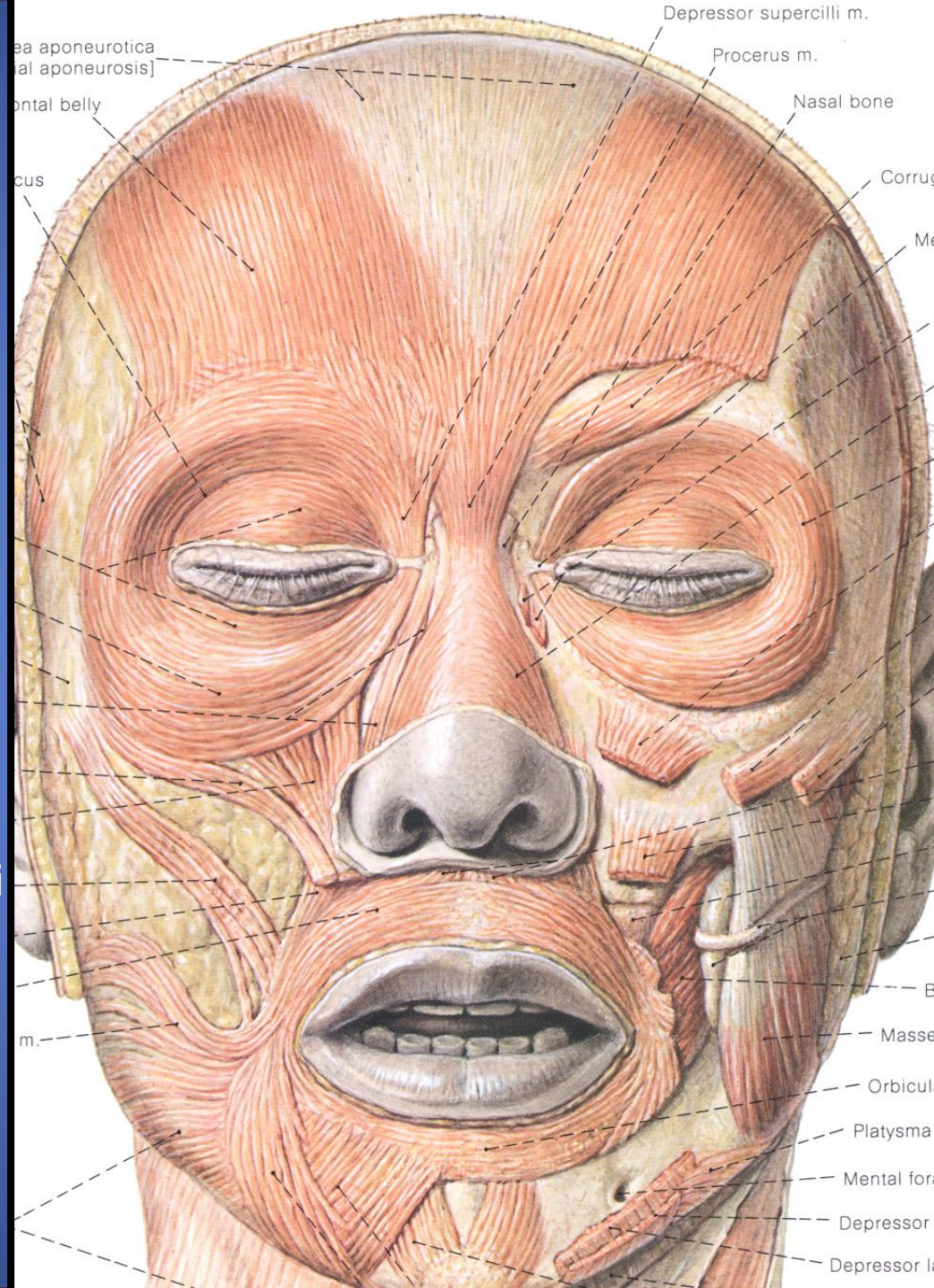
1. *Occipitofrontalis (frontal belly)*
2. *Corrugator supercilii*
3. *Procerus*
4. *Nasalis*
5. *Depressor septi*



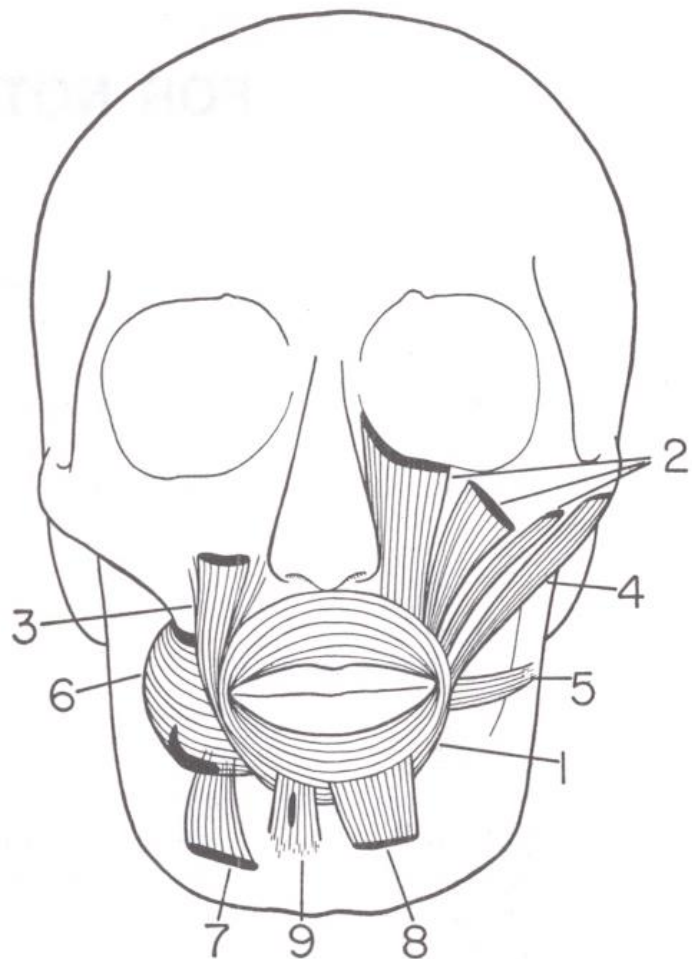


# Ağız Kasları

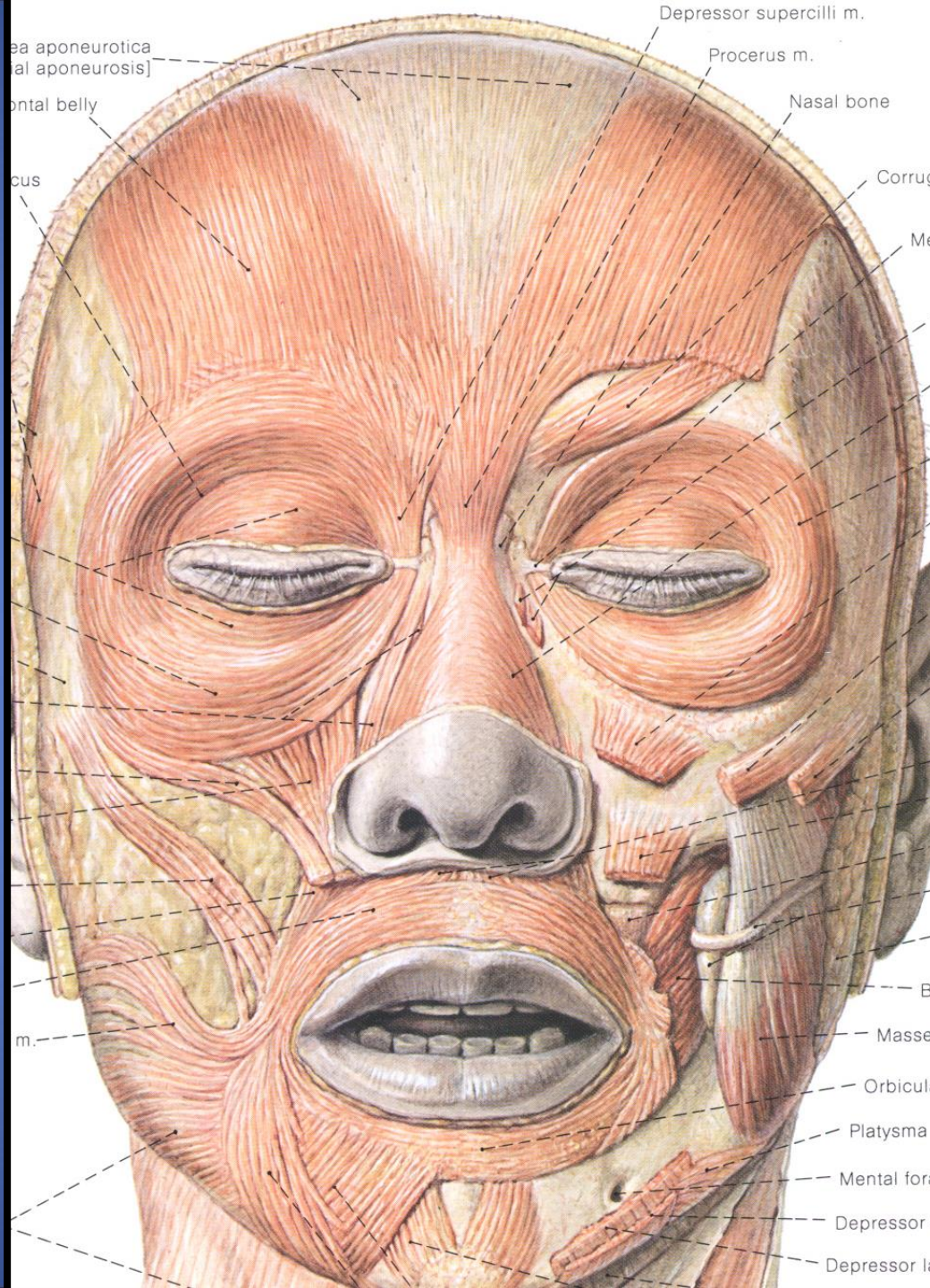
- M. Orbicularis oris
- M. Depressor labii inferioris
- M. Depressor anguli oris
- M. Mentalis
- M. Levator labii superioris
- M. Levator anguli oris
- M. Zygomaticus major
- M. Zygomaticus minor
- M. Levator labii superioris alaeque nasi
- M. Risorius
- M. Buccinator





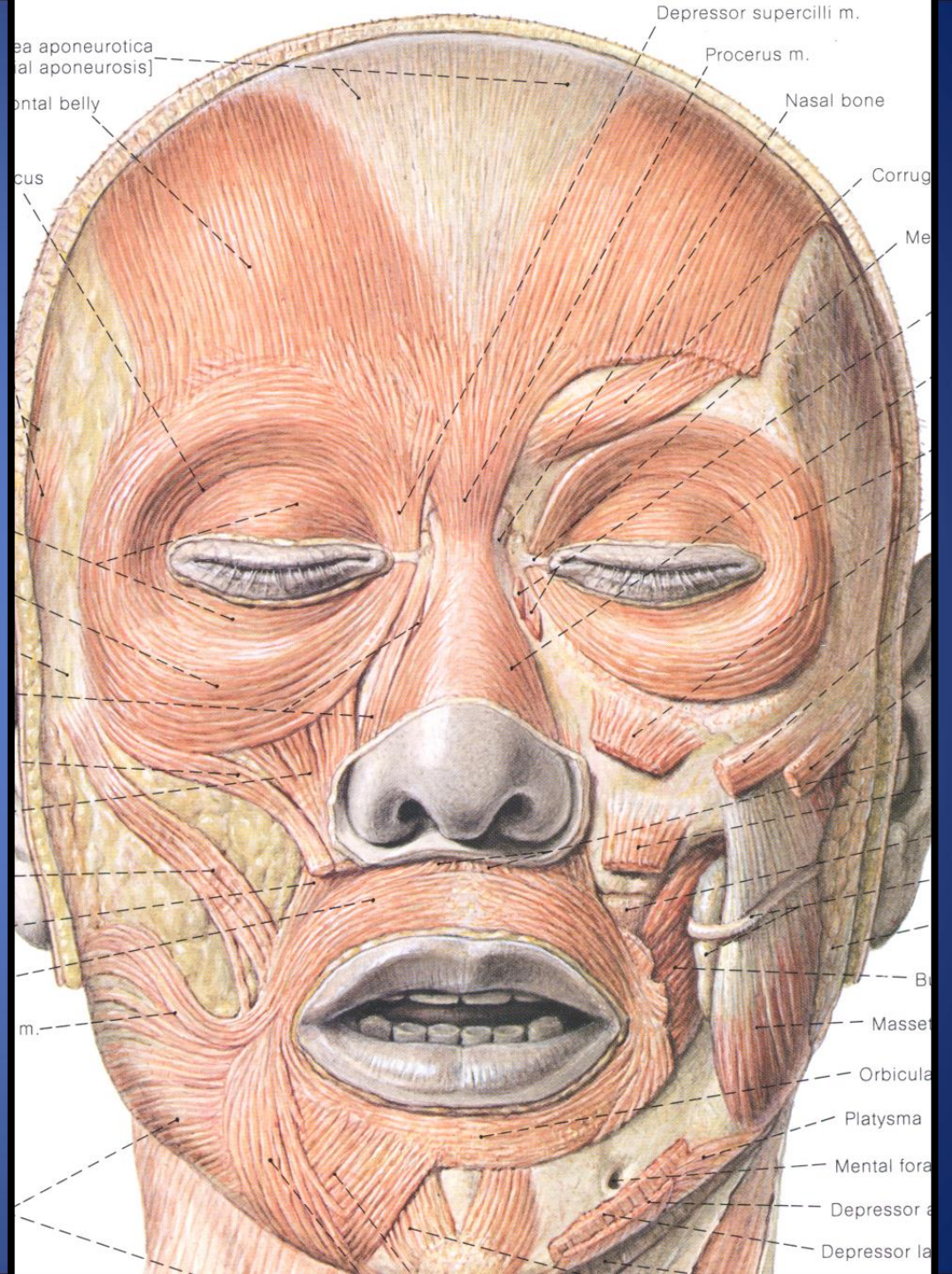


1. *Orbicularis oris*
2. *Zygomaticus minor*
3. *Levator anguli oris*
4. *Zygomaticus major*
5. *Risorius*
6. *Buccinator*
7. *Depressor anguli oris*
8. *Depressor labii inferioris*
9. *Mentalis*





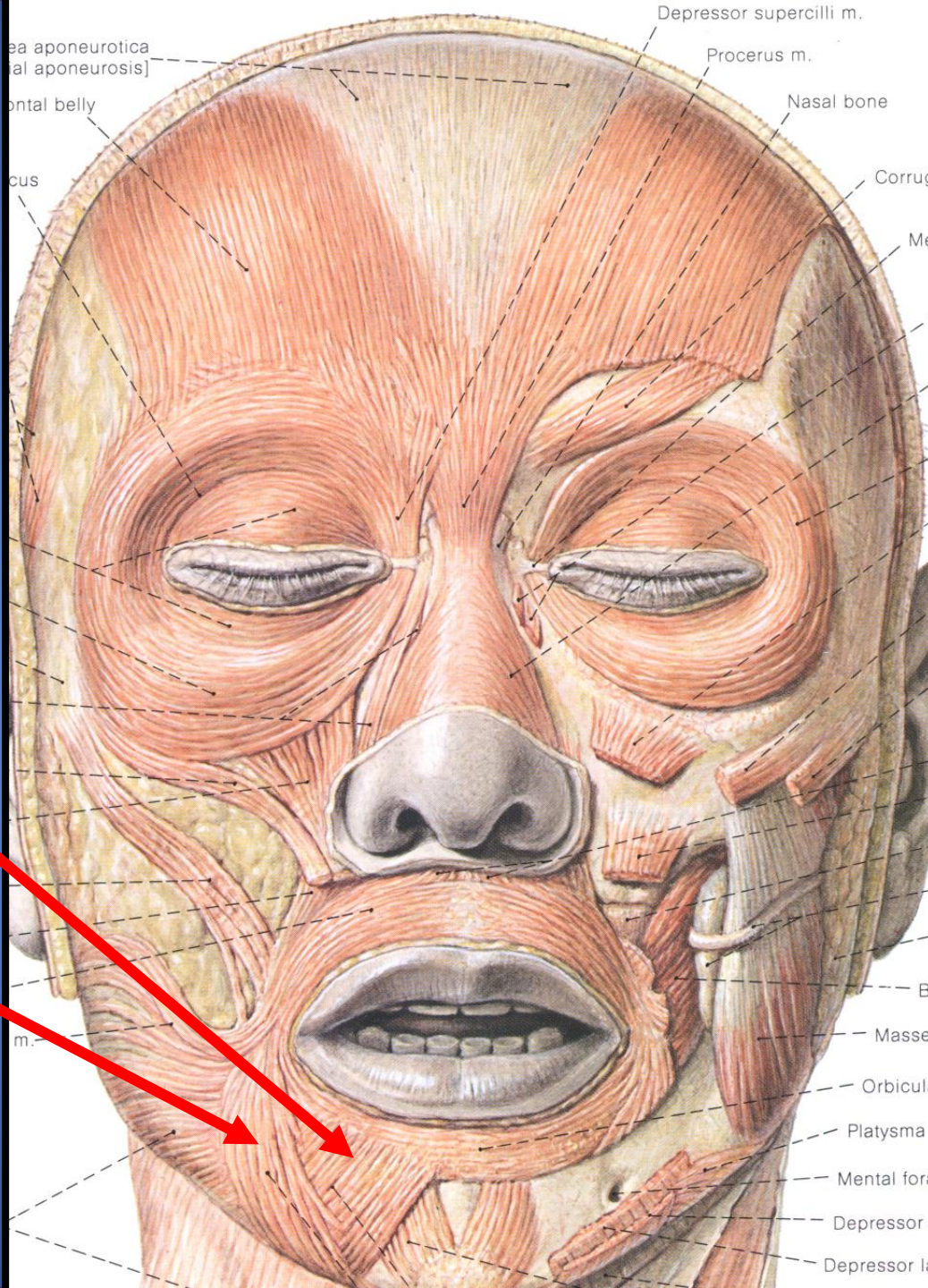
# M. Orbicularis oris





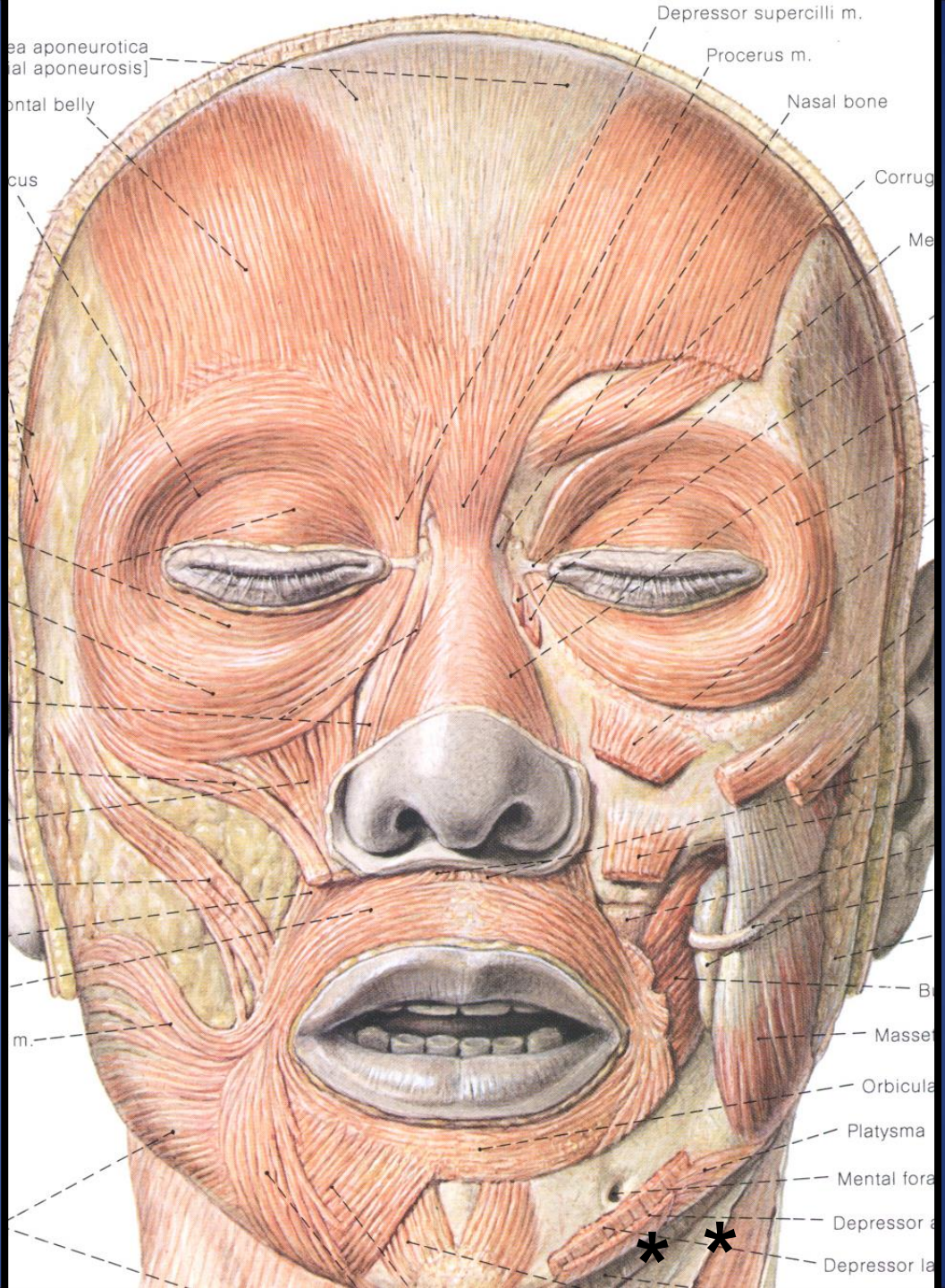
**M. Depressor labii inferioris**

**M. Depressor anguli oris**



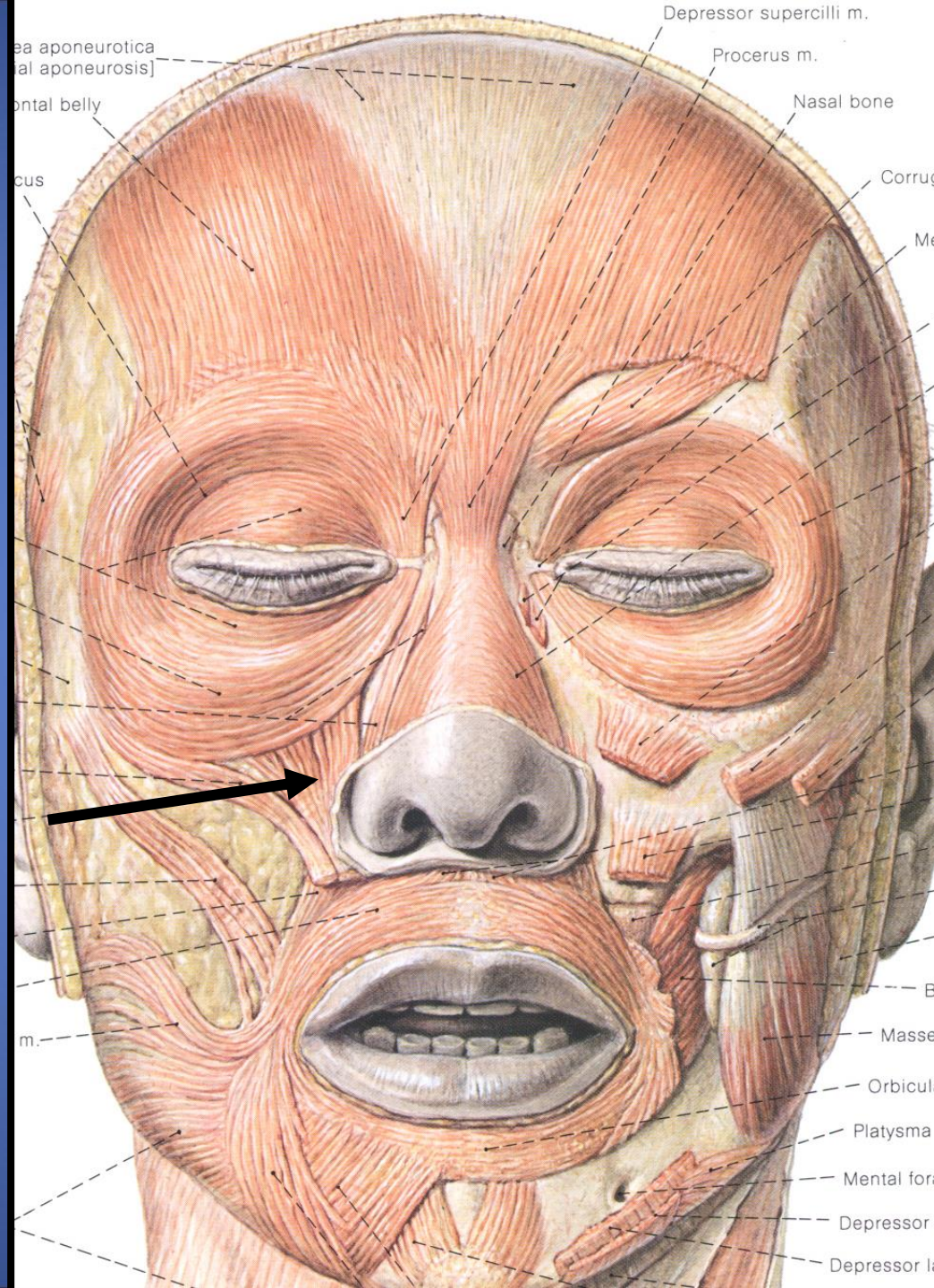


# M. Mentalis



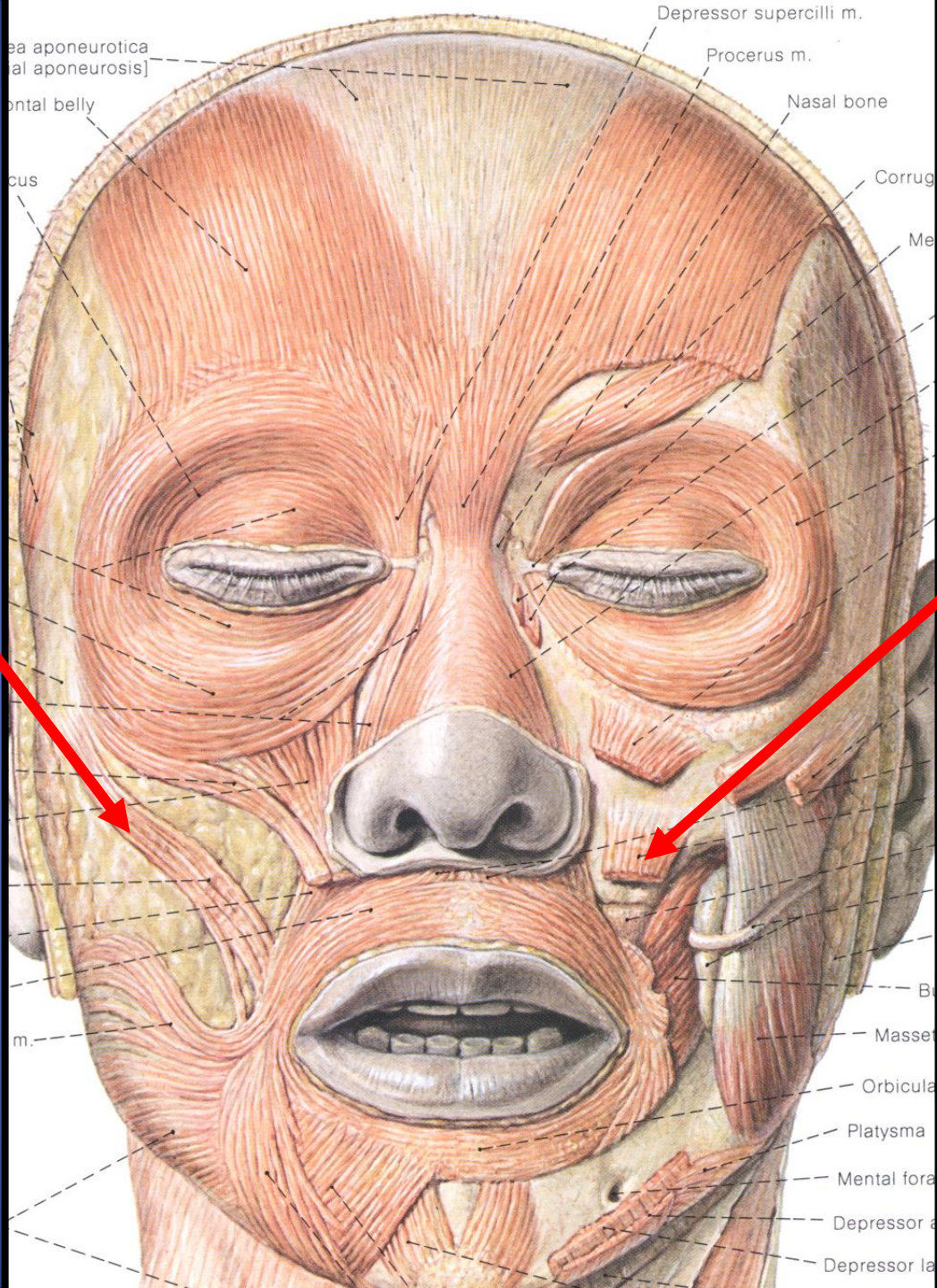


# M. Levator labii superioris





**M. Zygomaticus  
major**



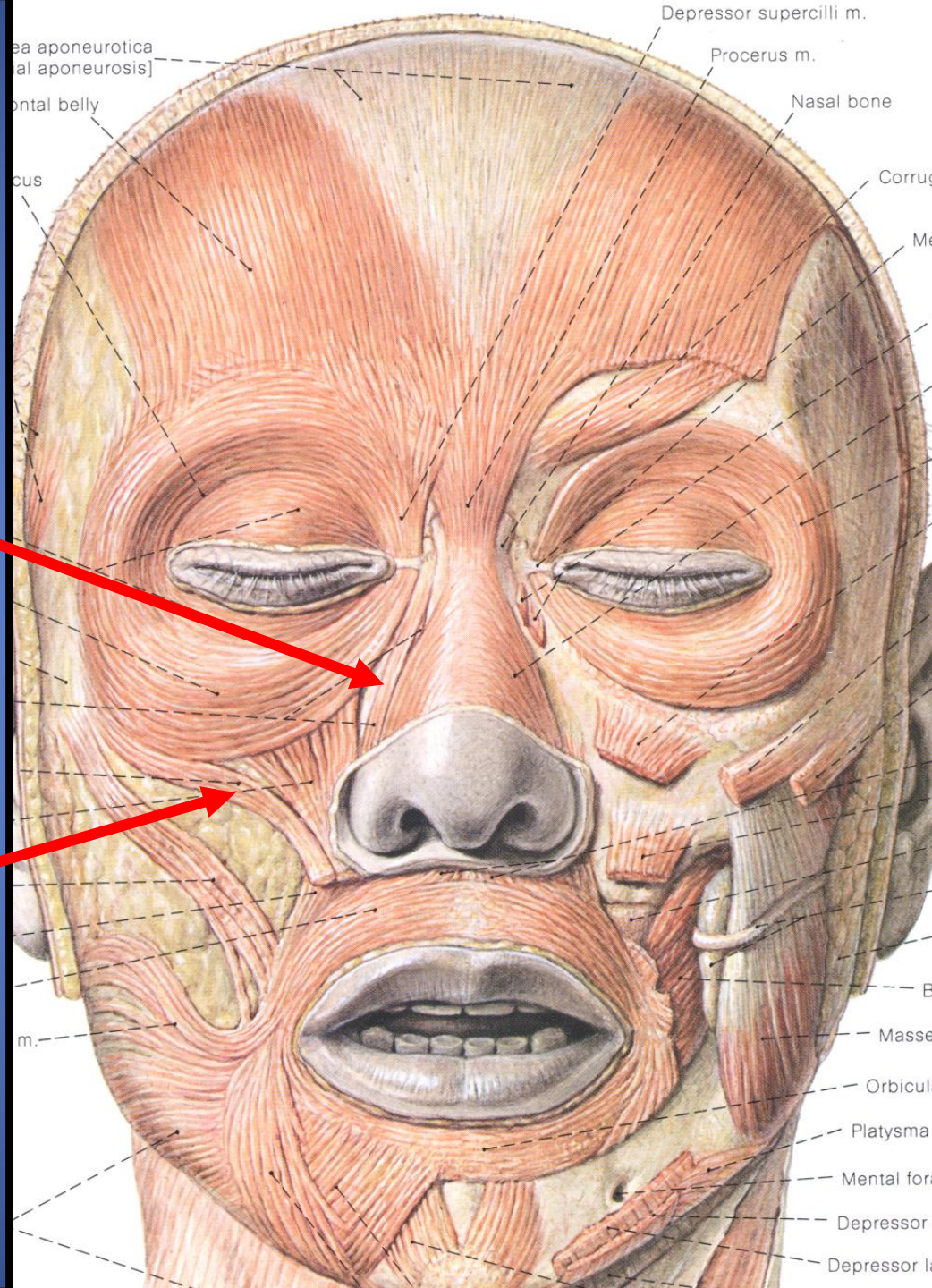
**M. Levator  
anguli  
oris**





**M. Levator labii superioris  
alaque nasi**

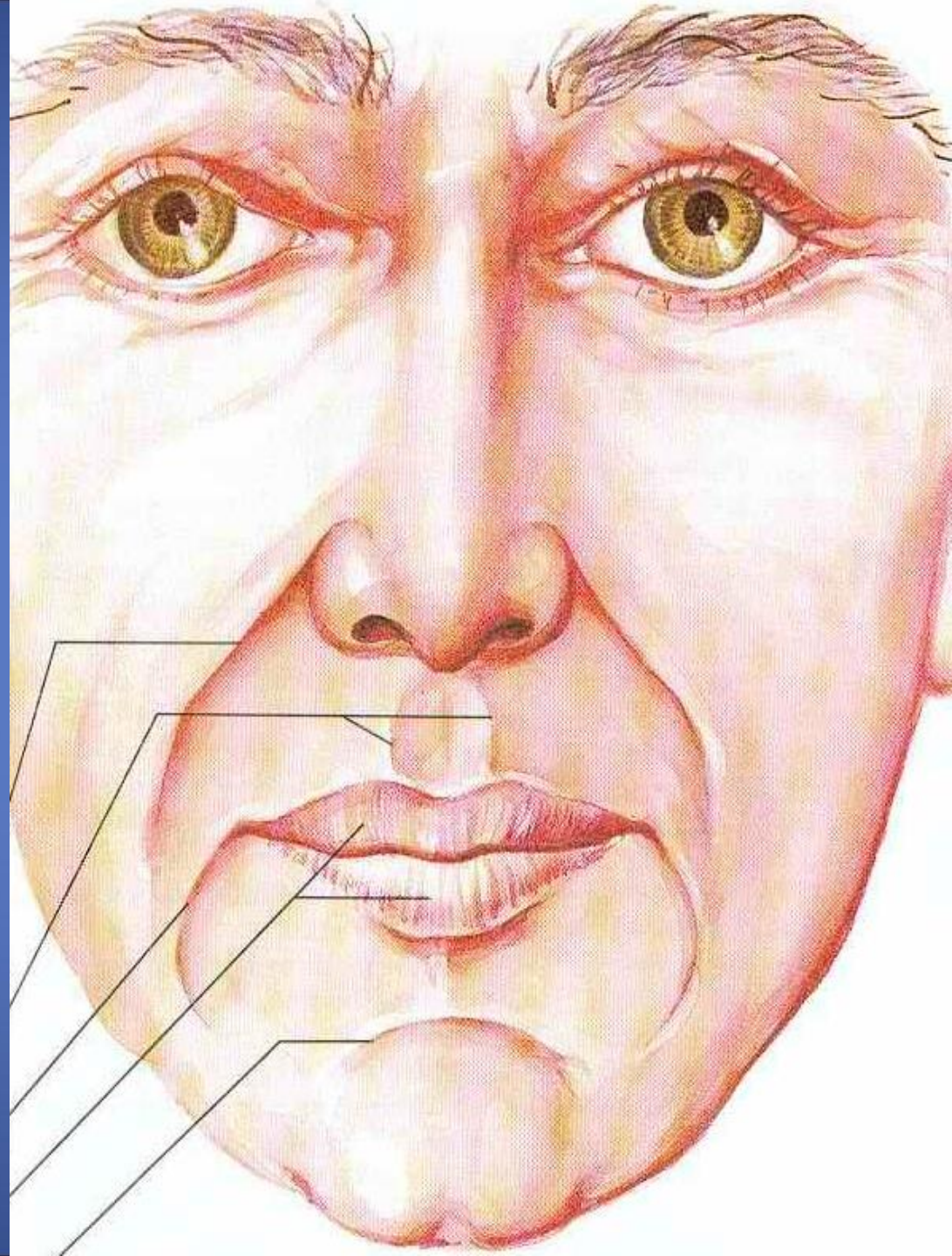
**M. Zygomaticus minor**





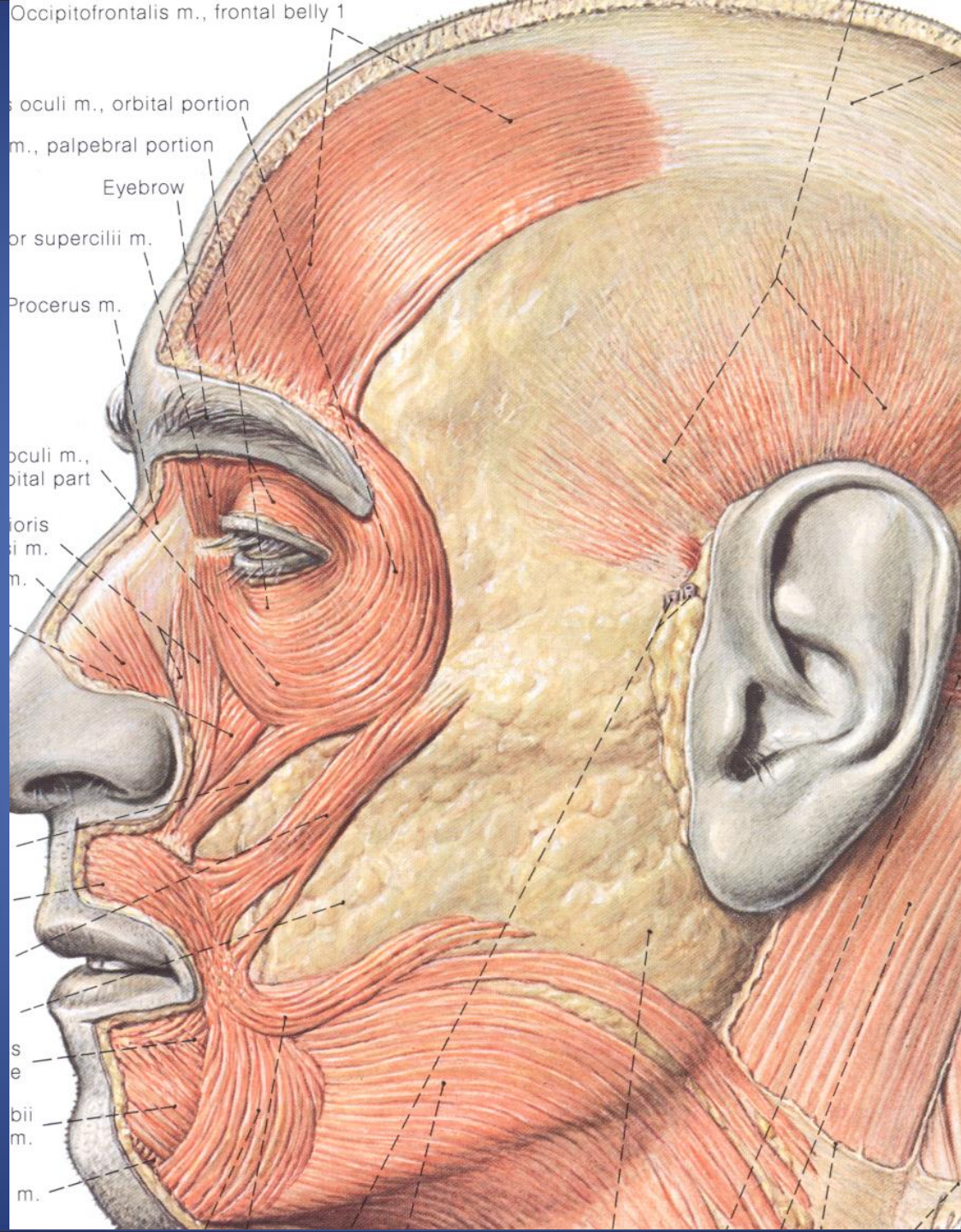
# Sulcus Nasolabialis

- M. Levator labii superioris
- M. Levator labii superioris alaeque nasi
- M. Zygomaticus minor



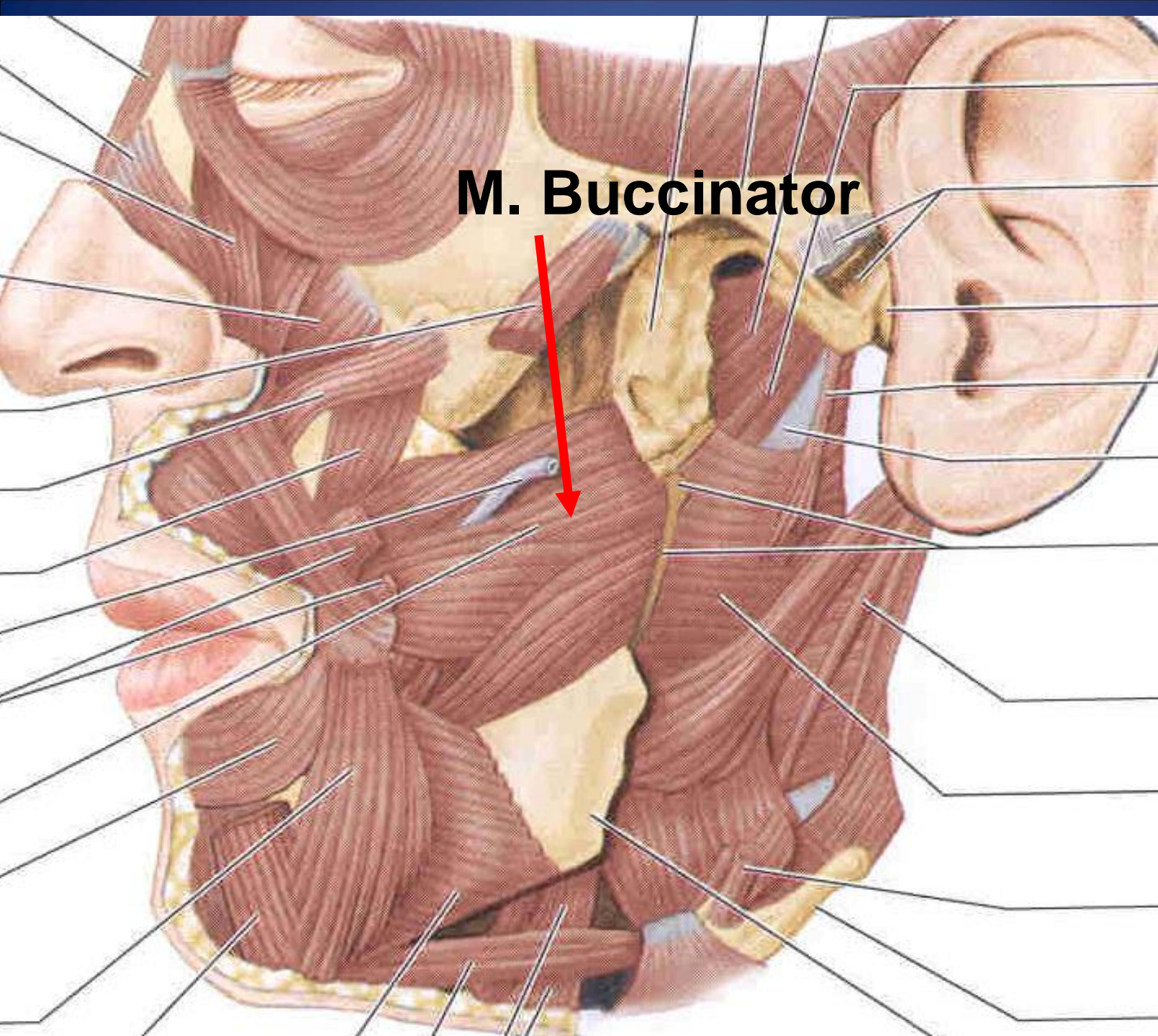


# M. Risorius



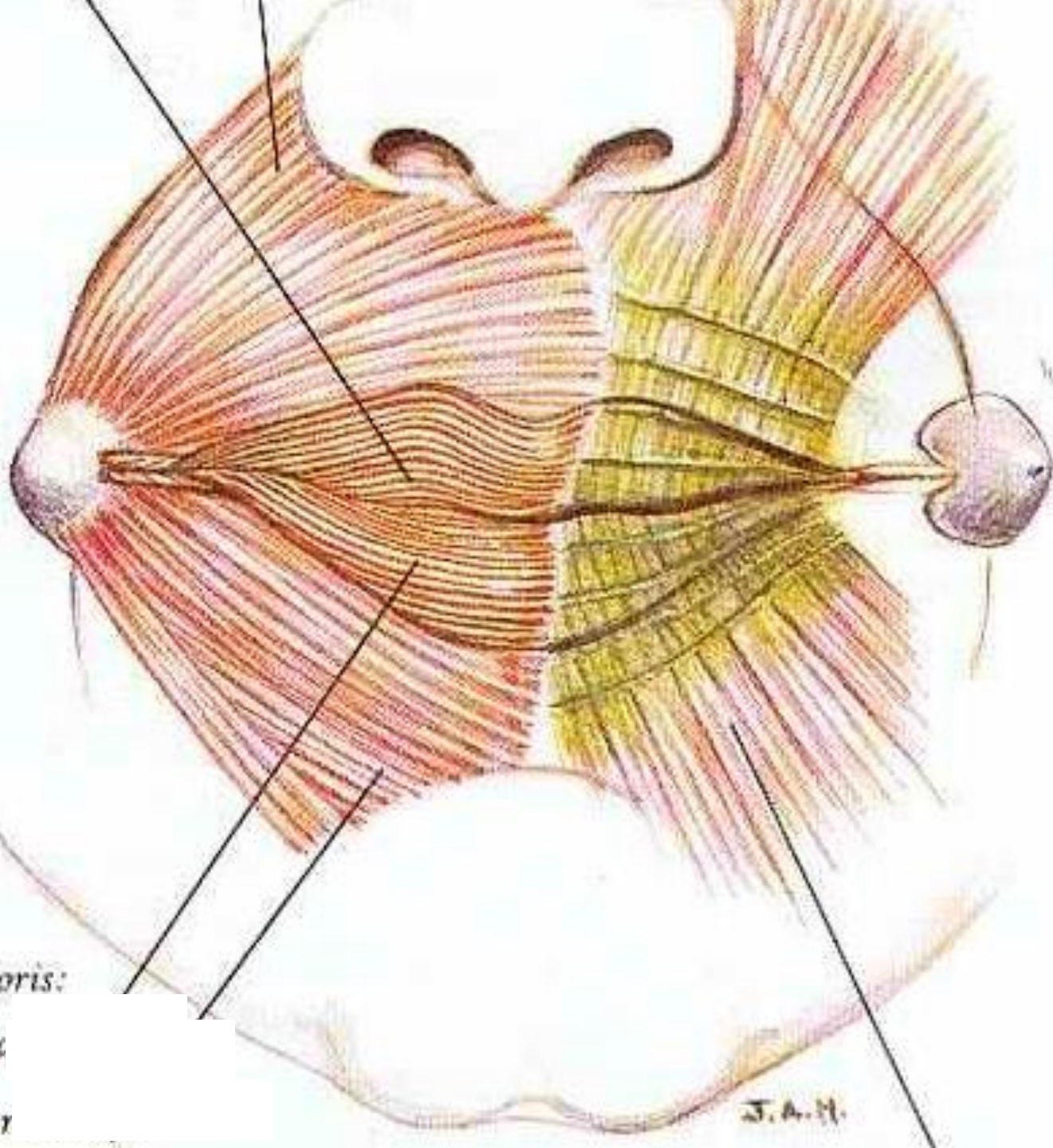


# M. Buccinator





# Modiolus

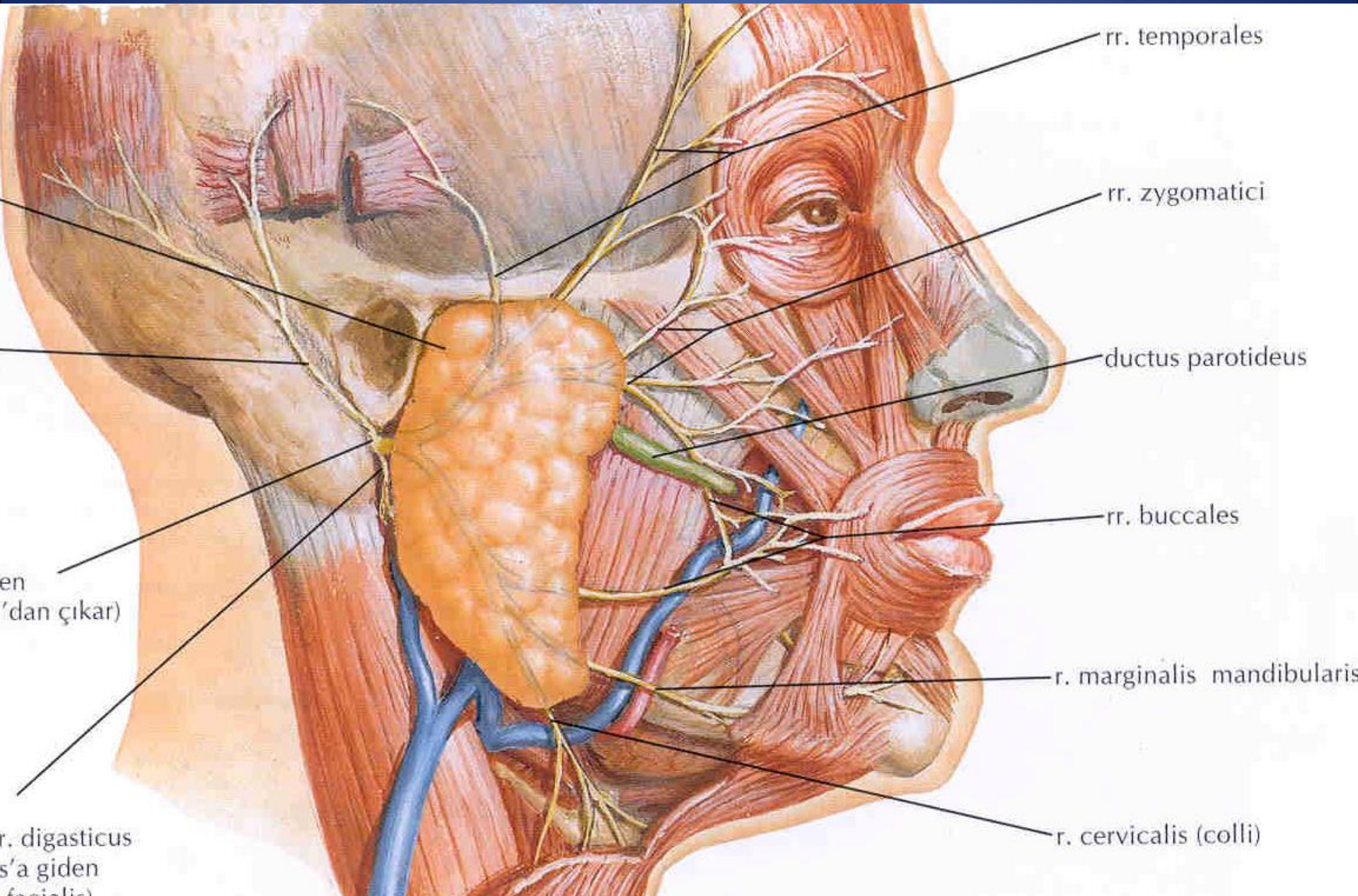


oris:

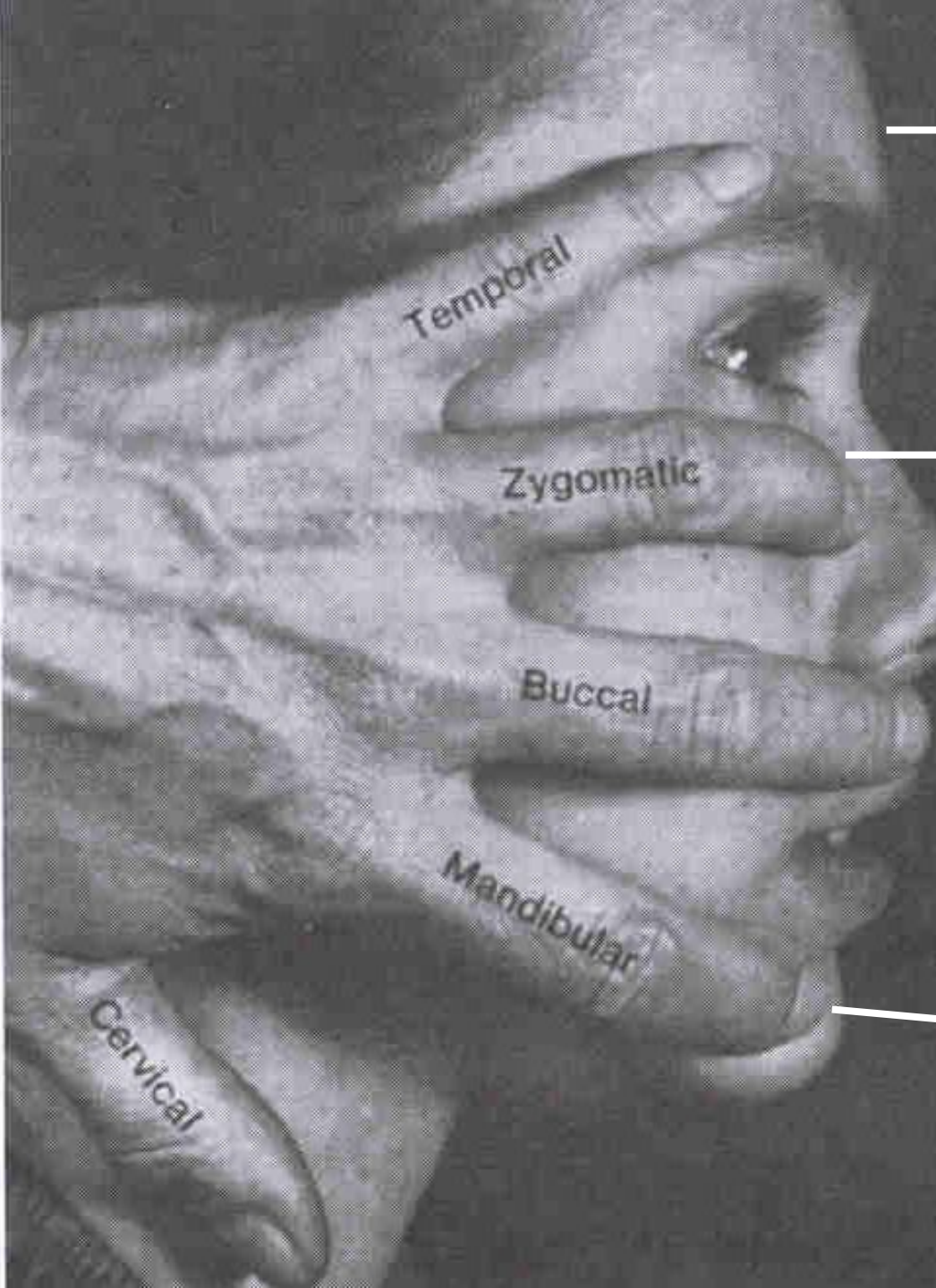
J.A.H.



# Nervus Facialis







m. Orbicularis oculi  
m. Corrugator supercilii  
m. Procerus

m. Orbicularis oculi

m. Levator labii sup. alaeque nasi  
m. Levator labii sup.

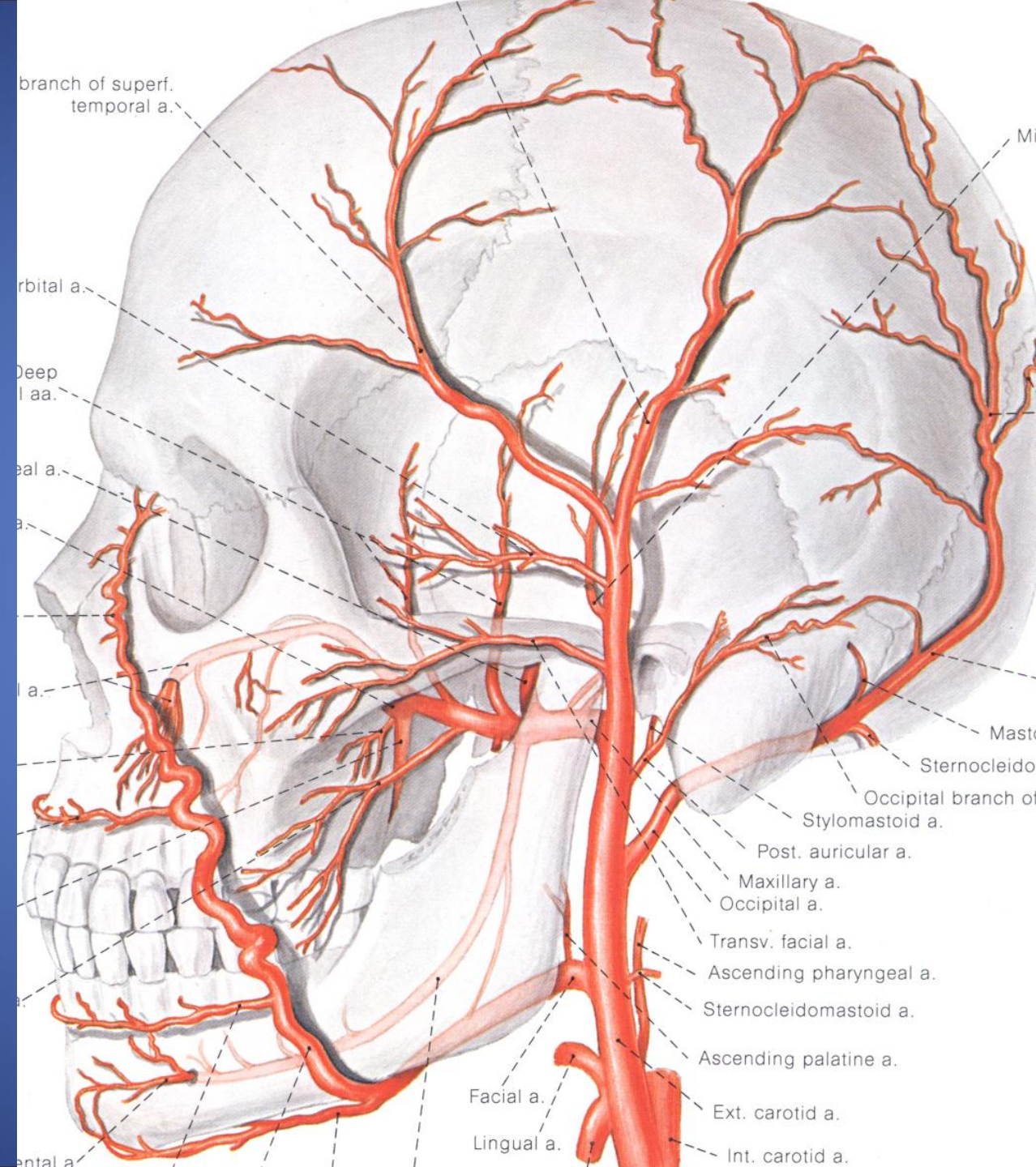
m. Zygomatic minor and major  
m. Levator anguli oris  
m. Orbicularis oris  
m. Depressor septi

m. Mentalis  
m. Depressor labii inf.  
m. Depressor anguli oris  
m. Orbicularis oris

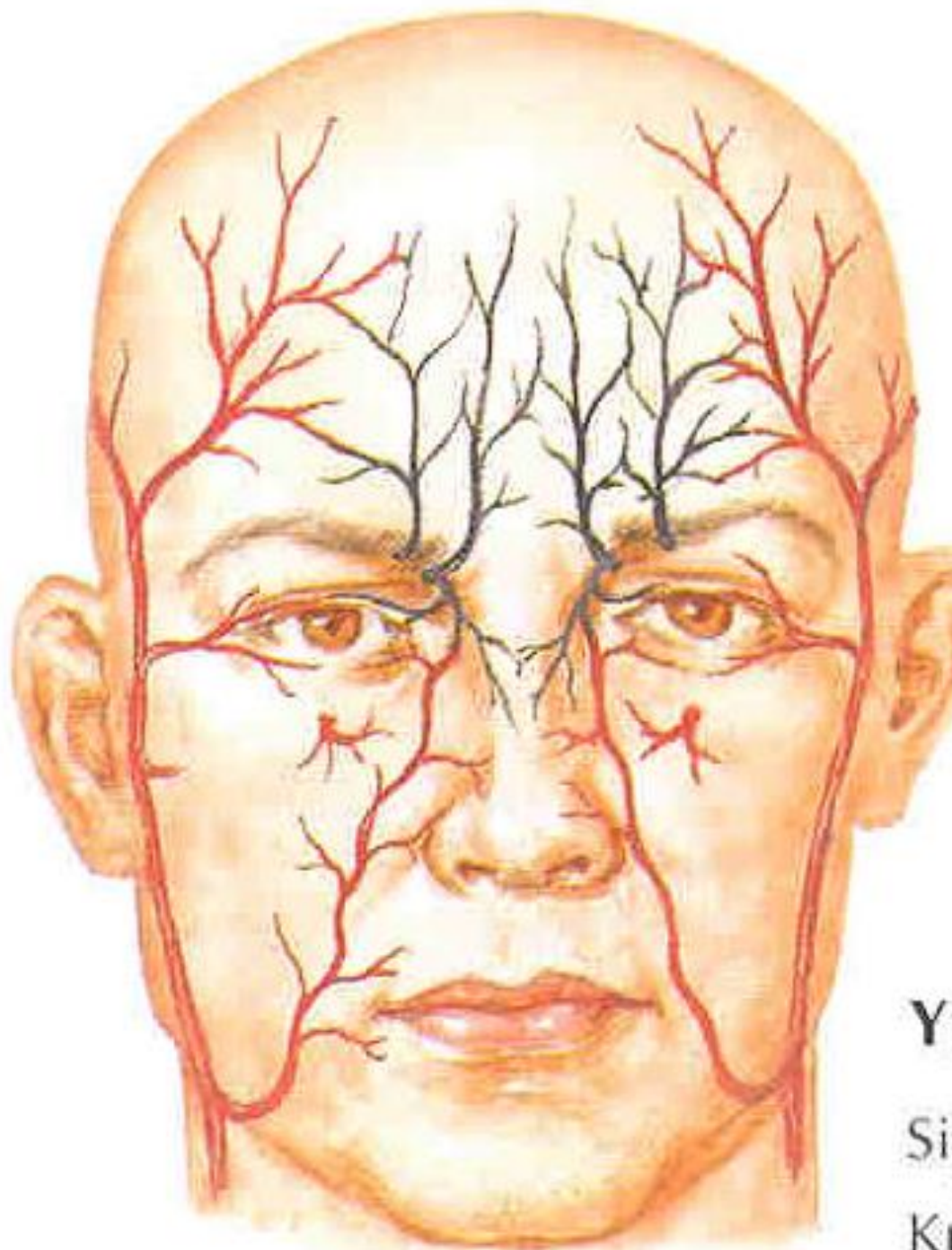


# Arterler

- 1- A. Facialis
  - 2- A. Maxillaris
  - 3- A. Temporalis Superficialis
- (A. Carotis Externa)
- 
- 4- A. Ophtalmica
- (A. Carotis Interna)







Y  
S  
K



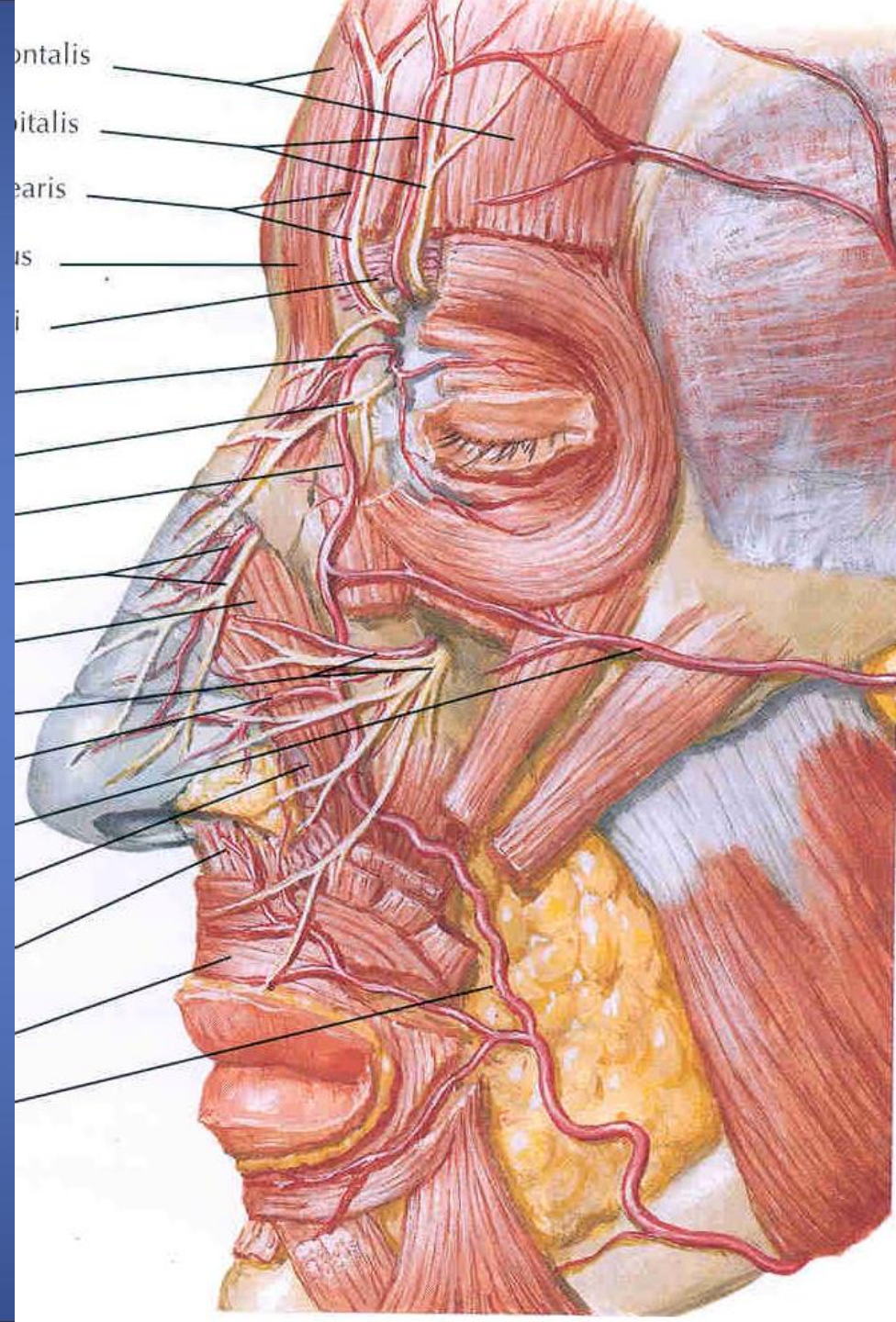
# Arteria Facialis

- A. Palatina Ascendens
- A. Tonsillaris
- A. Submentalis

Boyunda

- A. Labialis inferior
- A. Labialis superior
- A. Nasalis lateralis
- A. Angularis

Yüzde

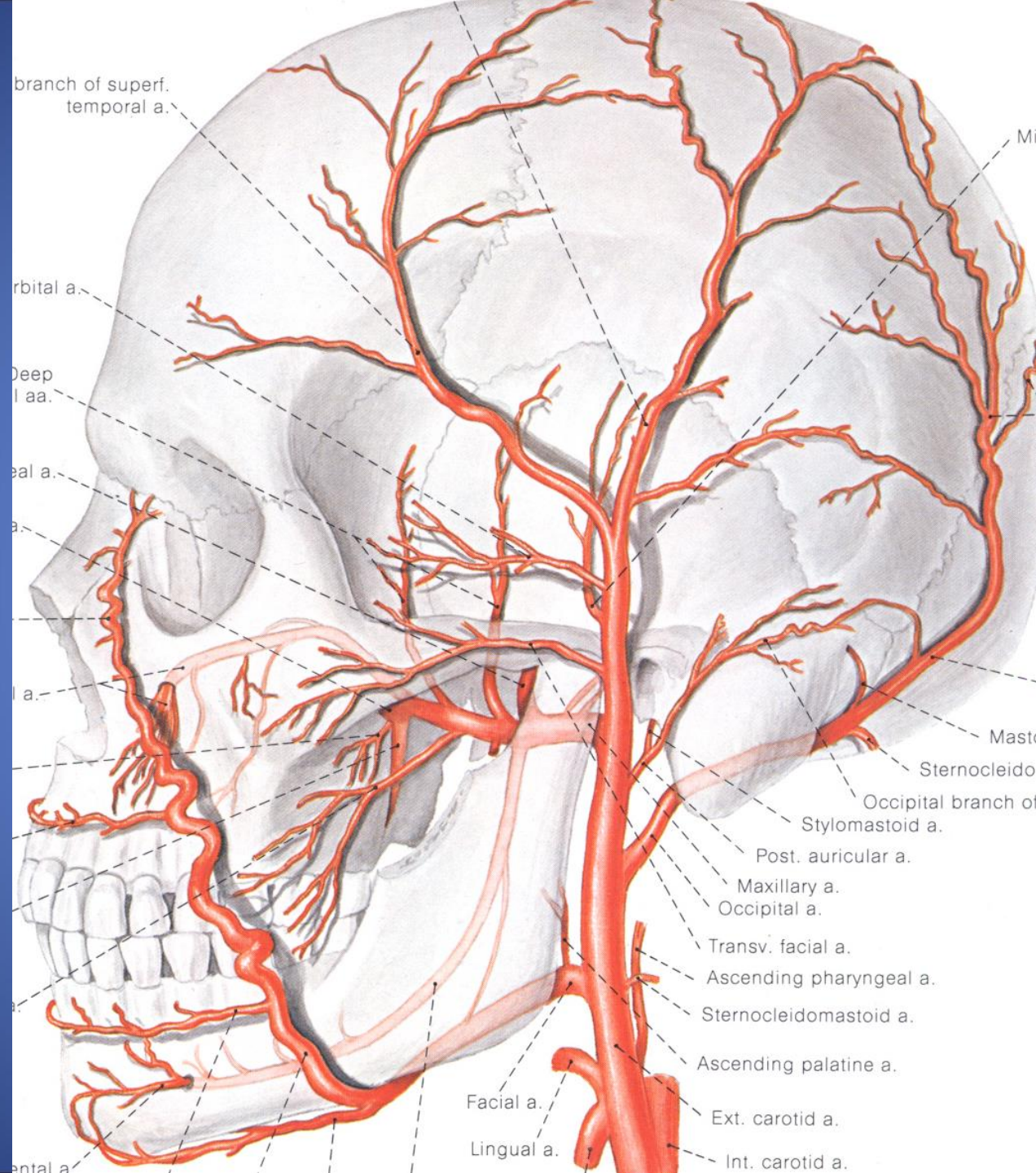




# Arteria Maxillaris

- A. Buccalis

- A. Infraorbitalis

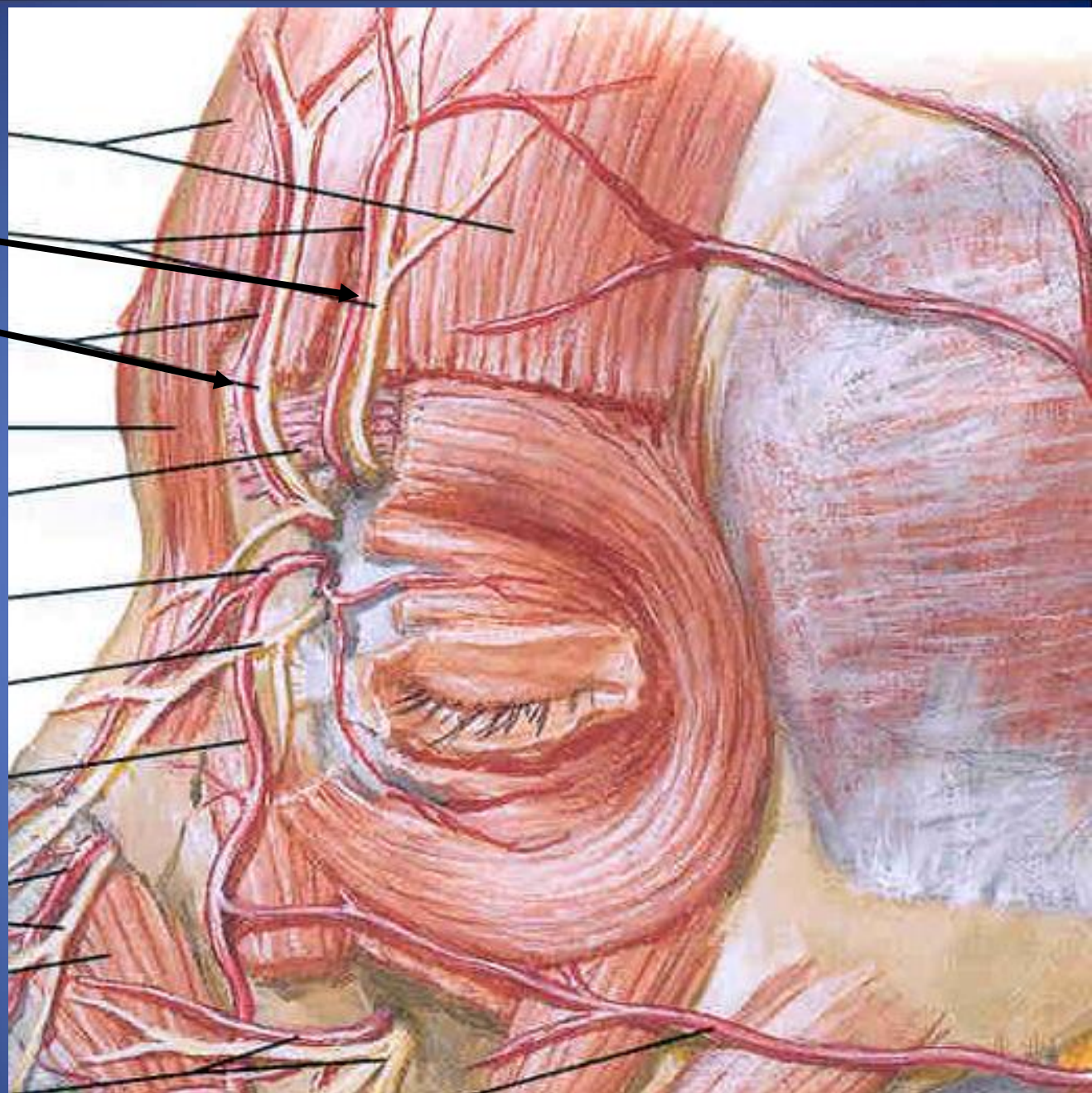




# Arteria Ophtalmica

- A. Supraorbitalis

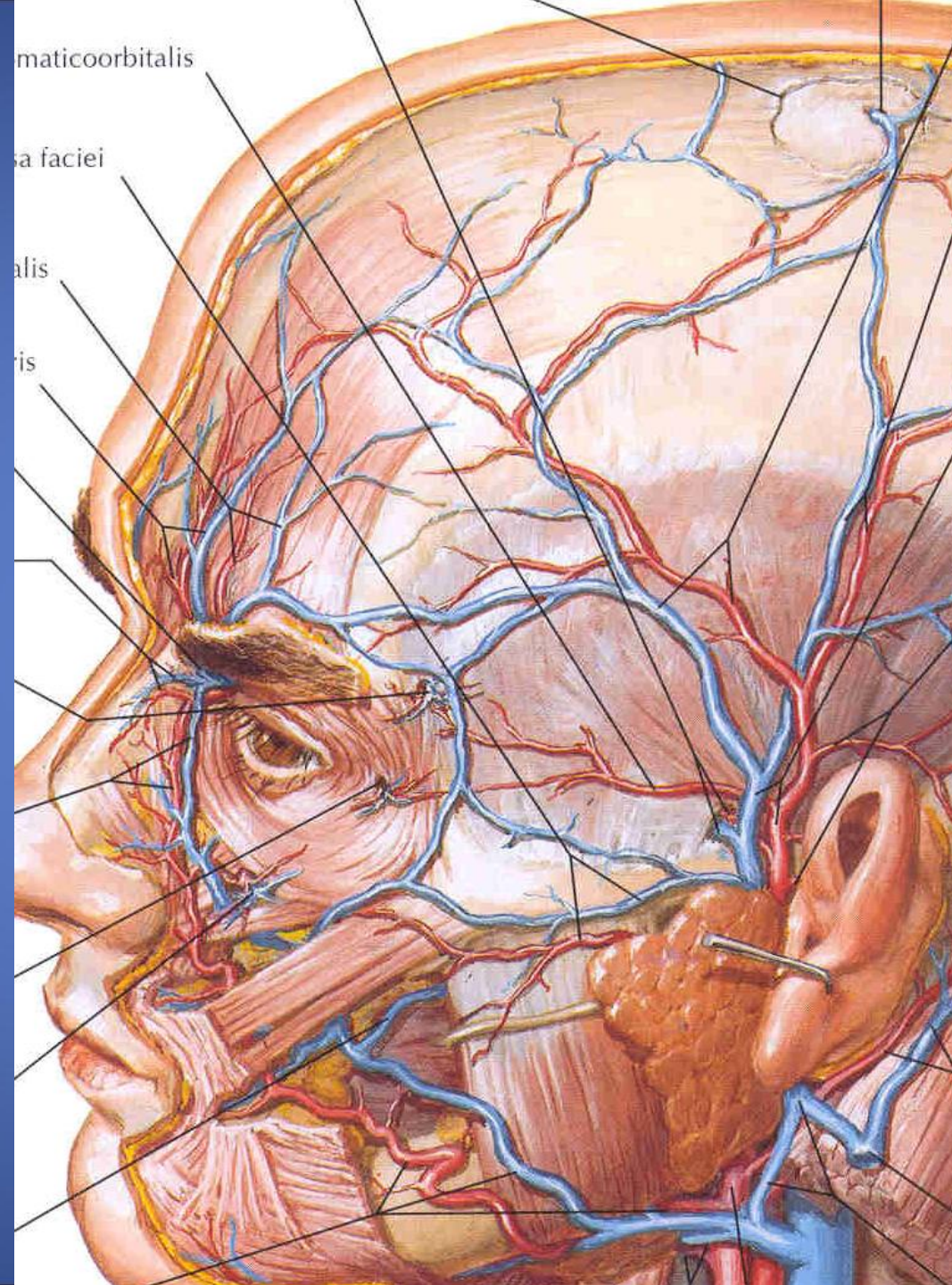
- A. Supratrochlearis





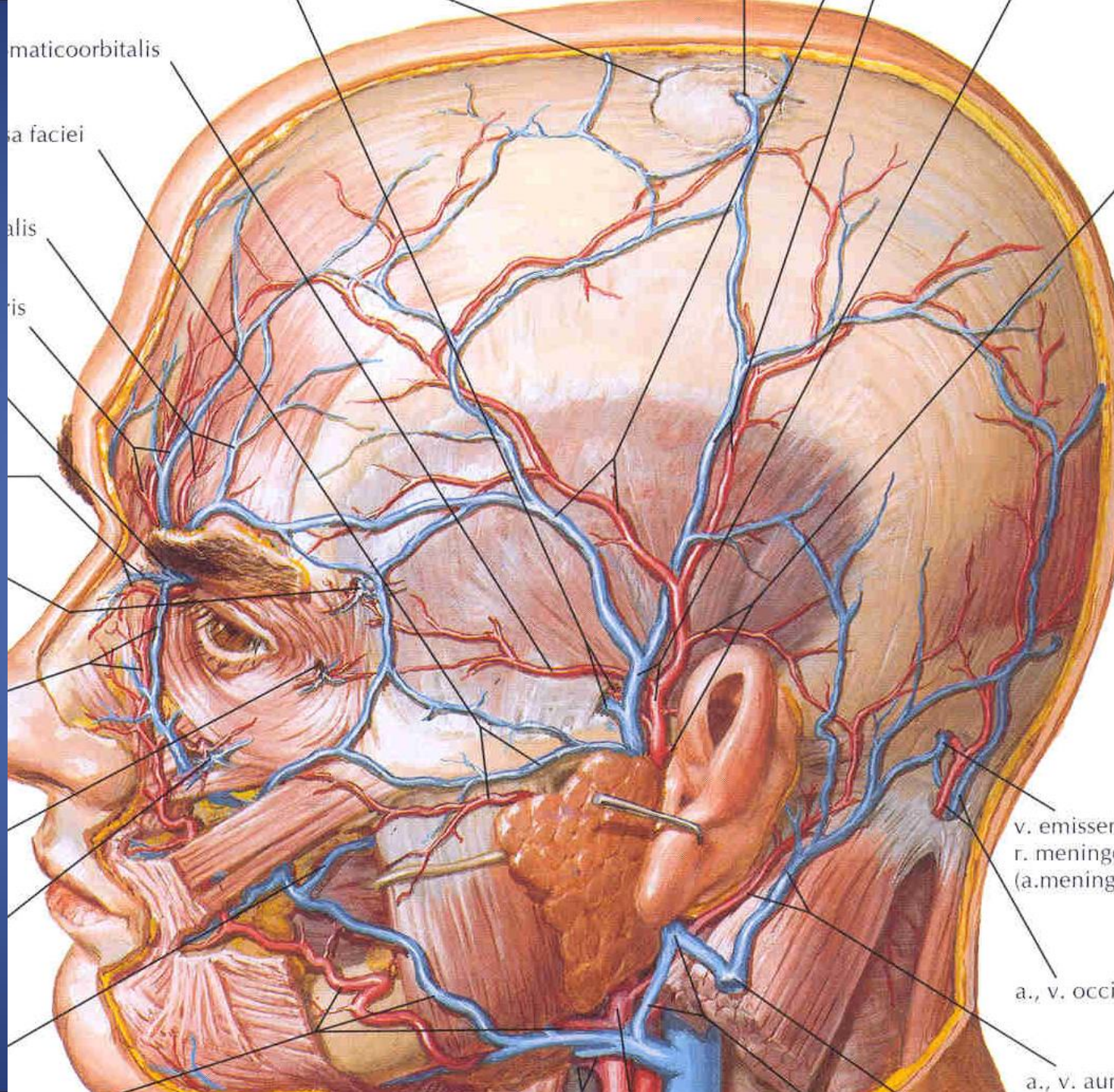
# A. Temporalis Superficialis

- A. Transversa faciei





# Venler





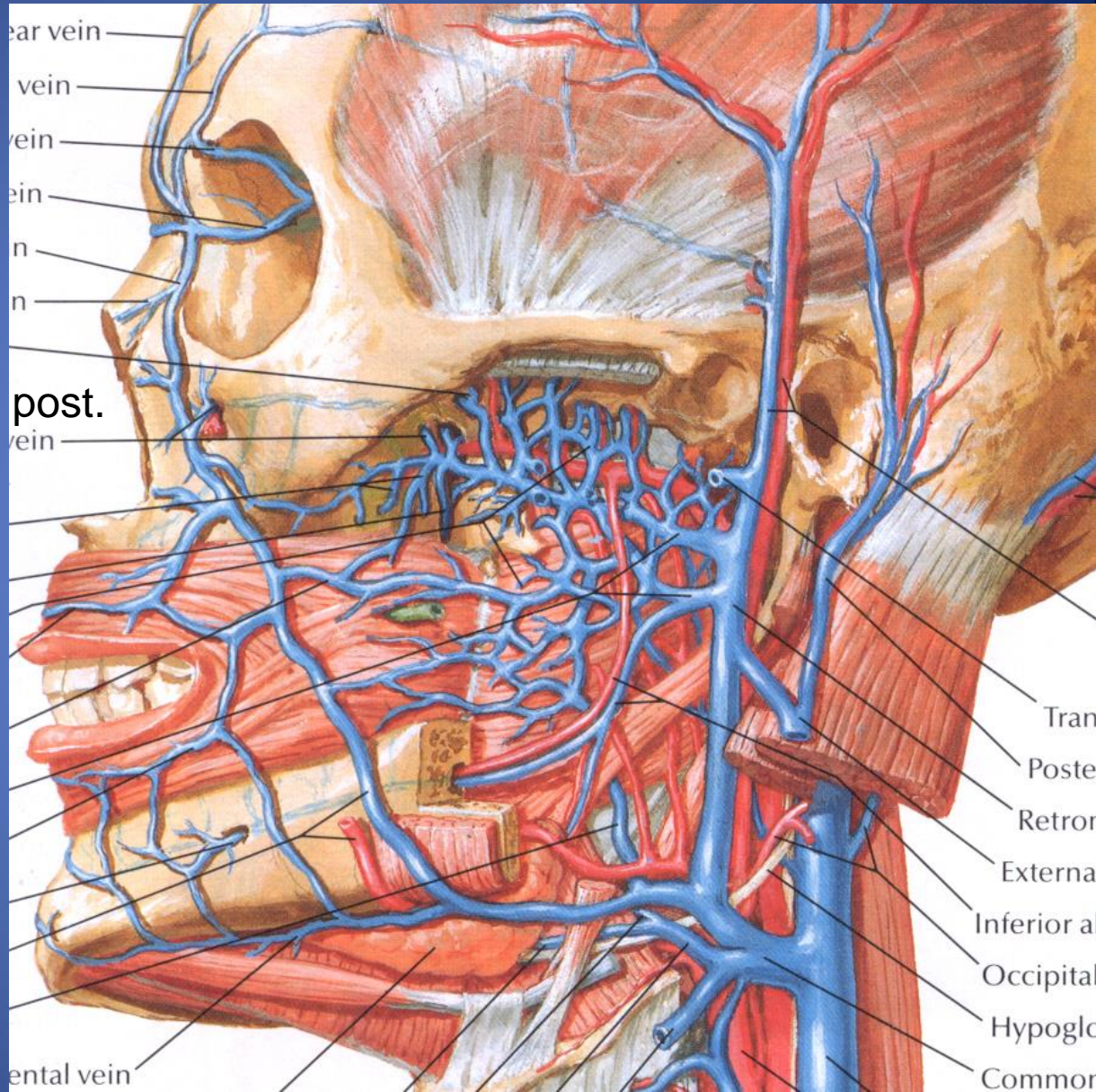
V. Maxillaris  
V. Temporalis superficialis

V. Retromandibularis

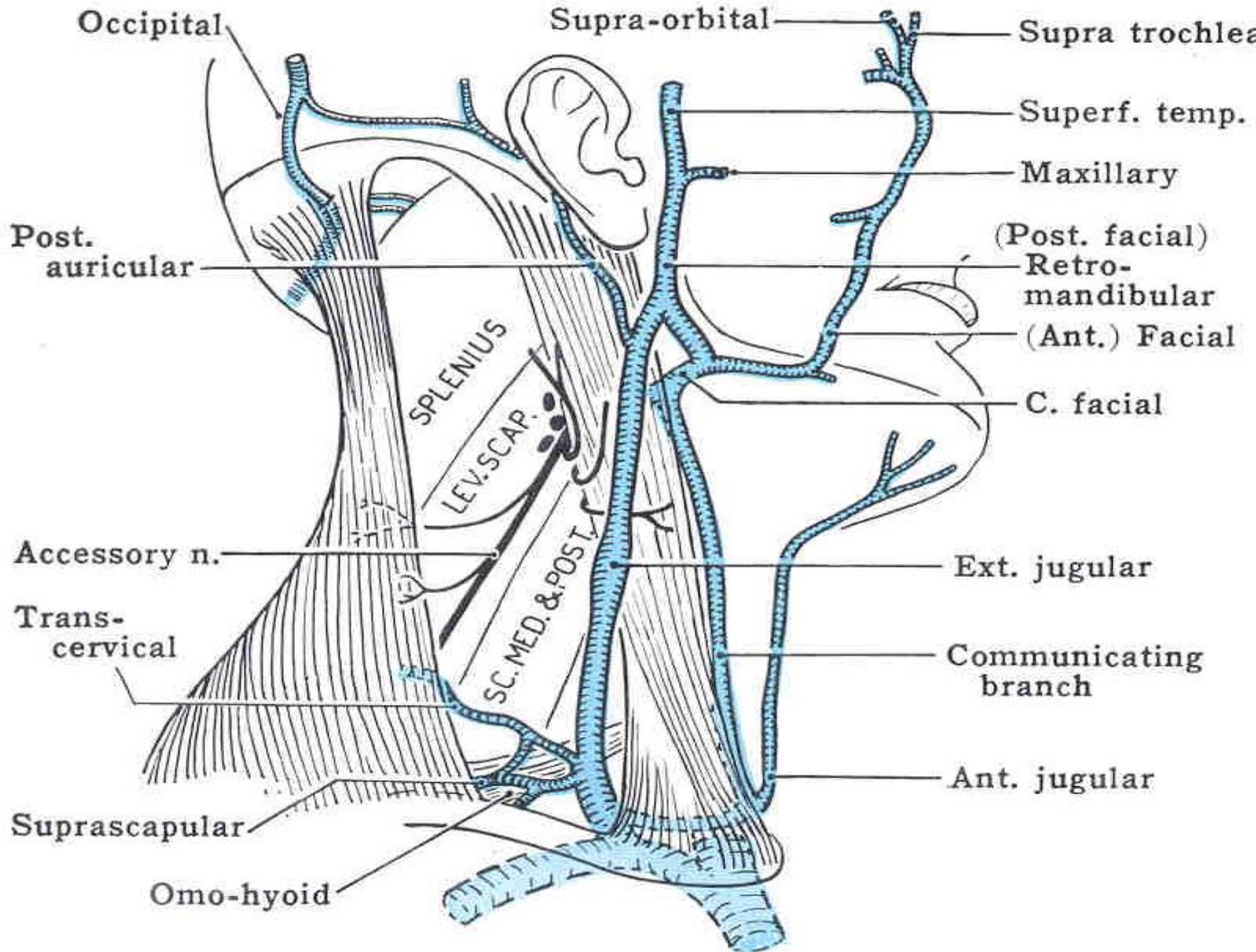
V. Facialis      V. Auricularis

V. J. I

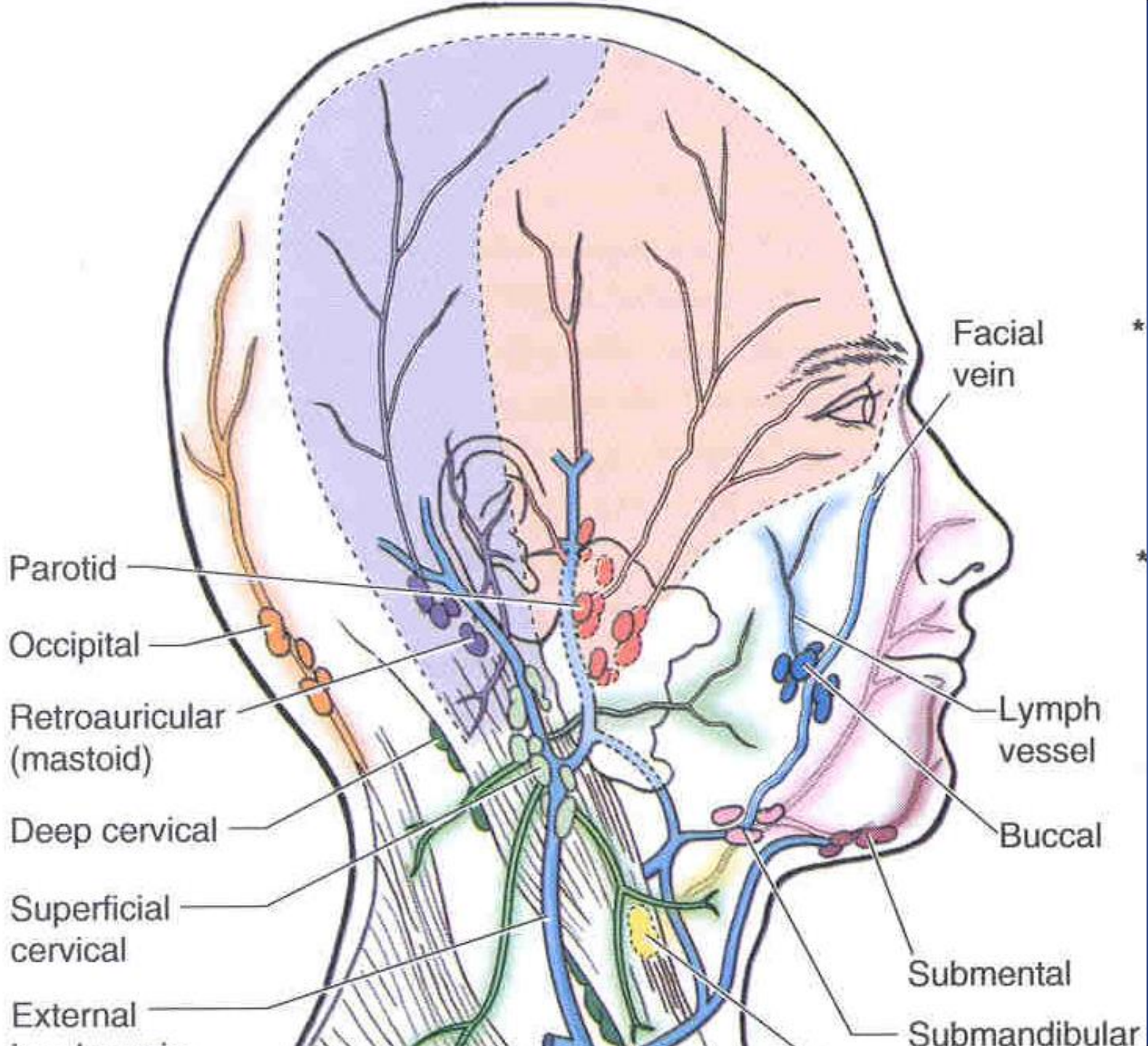
V. J. E













# V. Facialis Tromboflebiti

