

Unusually severe limitation of the jaw attributable to fibrodysplasia ossificans progressiva: a case report with cone-beam computed tomography findings

Kaan Orhan, DDS, PhD,^{a,b} Lokman Onur Uyanik, DDS, PhD,^c Erkan Erkmén, DDS, PhD,^d and Yeliz Kilinc,^e
Ankara and Mersin, Turkey
UNIVERSITY OF ANKARA AND NEAR EAST UNIVERSITY

Fibrodysplasia ossificans progressiva (FOP) is a rare hereditary connective tissue disease characterized by the progressive ectopic ossification of ligaments, tendons, and facial and skeletal muscles throughout life. Symptoms begin in childhood as localized soft tissue swellings. Immobility and articular dysfunction appear with involvement of the spine and proximal extremities. The temporomandibular joint (TMJ) is a critical component involved in the maxillofacial region, resulting in severe limitation of masticatory function, although TMJ involvement is rare. We report a case of FOP presenting as severely limited TMJ movements owing to ectopic calcification of the left coronoid process. In addition to the clinical examination, panoramic radiography and cone-beam computed tomography images were obtained. The case is presented and the clinical and imaging findings, differential diagnosis, and treatment modalities are discussed. (*Oral Surg Oral Med Oral Pathol Oral Radiol* 2012;113:404-409)

Fibrodysplasia ossificans progressiva (FOP) is a rare, catastrophic genetic disorder involving progressive hypertrophic ossification. It was first described by Guy Patin in 1648. Bauer and Bode used the term fibrodysplasia ossificans progressiva, also known as “stone man” deformity, in 1880.^{1,2} FOP is also known as myositis ossificans progressiva (MOP) and causes immobility through the progressive metamorphosis of skeletal muscle and soft connective tissue into a second skeleton of heterotopic bone.³

Classic FOP is characterized by congenital malformation of the great toes with shortening of the first metatarsal and proximal phalanx (hallux vagus) and by progressive heterotopic ossification in specific anatomic patterns, usually beginning in the first decade of life with a mean age of onset of 3 years.^{4,5}

The incidence is approximately 1 in 2 million, with about 700 reported cases. No sexual, racial, or ethnic predilection has been reported.⁴⁻⁶

The inheritance of FOP is autosomal dominant, with variable expression and penetration, although most cases are thought to be attributable to new mutations. The FOP gene has been mapped to chromosome 4q27-31.⁶ Additionally, FOP is linked to 2q23-24 via the gene encoding activin receptor IA (ACVR1), a bone morphogenic protein (BMP) type I receptor.^{2,5,7,8}

Patients usually present in childhood with painful fibroproliferative nodules that change to lamellar bone, bridging and immobilizing the joints of the axial and appendicular skeleton. The neck, spine, shoulders, elbows, and ankles are the active regions of ectopic ossification. Most patients are confined to a wheelchair, and become immobilized because of the progressive immobilization of the limbs, jaw, and chest wall, causing severe limitations on movement. Pulmonary complications and death are frequent, primarily in the fifth and sixth decades of life.^{1,2,9-11}

Maxillofacial involvement is also encountered in this patient group, leading to severe limitation of mouth opening. The temporomandibular joint (TMJ) is involved in approximately 70% of FOP cases and is often the last osseous articulation to be affected.^{9,12,13} Extra-articular ossification, progressing to ankylosis, is the major limiting factor encountered in these cases.⁹

This article presents a case of FOP of the TMJ along with panoramic radiography and cone-beam computed

This case was presented as a poster at the 12th European Congress of Dentomaxillofac Radiology, Istanbul, Turkey, June 2-5, 2010.

^aAssociate Professor, Department of Oral, Teeth and Jaw Radiology, University of Ankara, Faculty of Dentistry, Ankara, Turkey.

^bAssociate Professor, Department of Oral Teeth and Jaw Radiology, Near East University, Faculty of Dentistry, Mersin, Turkey.

^cAssistant Professor, Near East University, Faculty of Dentistry Department of Oral and Maxillofacial Surgery, Mersin, Turkey.

^dAssociate Professor, Gazi University, Faculty of Dentistry Department of Oral and Maxillofacial Surgery, Ankara, Turkey.

^eResearch Assistant, Gazi University, Faculty of Dentistry Department of Oral and Maxillofacial Surgery, Ankara, Turkey.

Received for publication Nov 18, 2010; returned for revision Mar 4, 2011; accepted for publication Mar 9, 2011.

© 2012 Elsevier Inc. All rights reserved.

2212-4403/\$ - see front matter

doi:10.1016/j.tripleo.2011.03.011

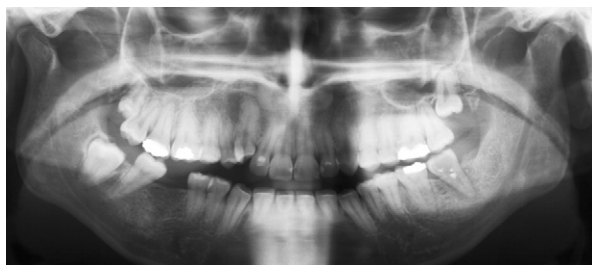

Fig. 1. Radiograph showing the periapical pathosis of the second left mandibular molar.

tomography (CBCT) findings to make a contribution to the clinical and radiological findings and differential diagnosis of FOP.

CASE REPORT

A 20-year-old female complained of restricted mouth opening and pain in the lower left jaw. Her chief complaint was swelling in the left molar region. The patient had suffered from FOP since childhood. She had no siblings and her parents were not consanguineous. There was no family history of any similar disease. Her physician diagnosed the patient's condition and confirmed a mutation in the *ACVR1* gene with a polymerase chain reaction evaluation and DNA sequence analysis.

The patient had a walking disorder because of ectopic calcification of the hips, ankles, and elbows. She also had a posture problem because of ectopic calcification of the neck, spine, and shoulders. She had no history of trauma, TMJ surgery, or steroid injection into the TMJ. The patient had restricted mouth opening, so an intraoral examination could not be performed. An extraoral examination revealed mild swelling on the left side of the mandible.

Based on the first examination, ankylosis was suspected, and a panoramic radiograph was taken, which showed periapical pathosis of the second left mandibular molar. Both TMJs showed degeneration and flattening of the condyles. However, there was no evidence of ankylosis of the TMJ (Fig. 1).

Initially, it was thought that the restricted mouth opening arose from an infection, with possible spread to the masticating muscles. CBCT (NewTom 3G, QR; Verona, Italy) was performed with 3-dimensional (3D) reconstruction to define the pathologic features more precisely. This showed bony extension of the left coronoid process with ankylosis to the skull base medial to the left zygomatic arch in the area of the left temporal muscle. Axial, sagittal, and coronal images also showed degeneration of both TMJs (Fig. 2). An interesting finding was the "bifid condyle" appearance in the right TMJ, possibly attributable to FOP (Fig. 3). Based on these findings, fusion of the hypertrophic mandibular coronoid processes to the skull base was thought to be the reason for the lack of TMJ mobility and restricted mouth opening.

The CBCT images also showed ossification of the right mastoid region (Fig. 2) and tall narrow cervical vertebrae bodies with large posterior elements, which caused the posture problem. The 3D reconstructed images demonstrated the

ectopic ossification of the cleft coronoid process that was responsible for the limited jaw mobility and restricted mouth opening (Fig. 4). The patient was referred to surgery for reconstruction of the coronoid process to improve her mouth opening.

DISCUSSION

FOP is a rare debilitating condition characterized by intermittent swellings within the soft tissues that progressively transform into bone.¹⁴ Defects in skeletal patterning are associated with progressive ossification of the large striated muscles in a specific order, leading to prolonged disability.^{15,16} The symptoms typically begin in childhood and congenital anomalies of the feet are an early diagnostic sign, bilateral short great toes (hallux vagus) being the most important.¹⁷ Patients with FOP have 2 skeletons: the normotopic and heterotopic skeletons. The normotopic skeleton forms during embryogenesis and the heterotopic skeleton develops after birth. During the first decade of life, children with FOP develop painful soft tissue swellings that transform soft connective tissue into bone.⁵ Maturing heterotopic bone generally forms rigid synostoses, thereby restricting motion and exacerbating the disability.⁶

The anatomical progression of heterotopic bone formation in FOP follows a characteristic temporal pattern. The dorsal, axial, cranial, and proximal regions of the body are typically involved early in life, followed by the ventral, appendicular, caudal, and distal regions. The main target is the axial musculature. Significant axial involvement of the neck, spine, and shoulders was present in our case.¹⁵ The diaphragm, tongue, extraocular, cardiac, and smooth muscles are spared in FOP.⁵ The severity of FOP varies among patients, although most affected individuals become immobilized because of extensive heterotopic bone formation and the loss of joint flexion by the third decade, leaving them dependent on assisted devices for the activities of daily living.¹¹

The etiology of FOP is beginning to be understood.³ Recently, a recurrent mutation in *ACVR1/ALK2*, a BMP type I receptor, was reported in FOP cases. This mutation predicts destabilization of the glycine-serine domain, consistent with an overactive BMP signaling pathway as the underlying cause of the ectopic ossification and joint fission in FOP.^{3,5,8}

Previously, Lucotte et al.¹⁸ mapped FOP to chromosome 17q21-22. They suggested that *SMAD*, a pathway-specific gene, and other genes were responsible for the possible linkage, which warrants further investigations. Feldman et al.¹⁹ identified the *4q27-31* gene as a possible cause of FOP. Recently, Shore et al.⁸ mapped FOP to chromosome 2q23-24 using linkage analysis. In a recent review, Kaplan et al.³ stated that BMP signal-

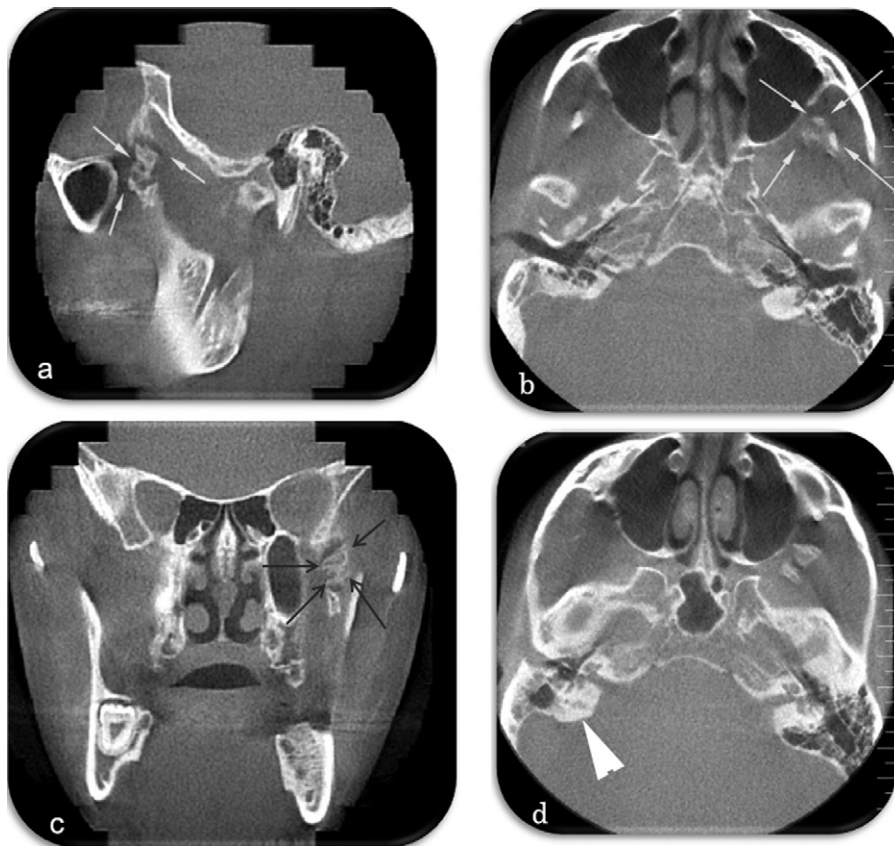

Fig. 2. **a–c**, Sagittal, axial, and coronal CBCT images show a radiopaque ossification under the left zygomatic arch through the skull base (*arrows*). The relationship between the surrounding muscles cannot be visualized on CBCT images. **d**, The axial image also shows marked opacification in the right mastoid region (*arrowhead*).

ing in FOP remains undetermined and further investigation should be conducted.

Both genetic and environmental factors affect the onset of FOP. Trauma has been related to most cases, although there are also cases with no history of injury.²⁰ Bone formation can be triggered by trauma to the muscles, surgical intervention, intramuscular injection, venipuncture, and dental therapy. An exaggerated inflammatory response mechanism has been suggested for the pathogenesis of FOP. Gannon et al.¹⁰ reported the role of mast cells in the development of FOP lesions. Shafritz et al.²¹ demonstrated the dysregulation of BMP-4 production and enhanced levels of BMP-4 mRNA and protein in lymphoblastoid cells in FOP patients.

Flare-ups of FOP involving the TMJs can cause the jaw to fuse, and make eating and performing dental procedures difficult. The TMJs are characteristically among the last joints to be affected by FOP. However, involvement of the TMJs has been reported following dental procedures or oral trauma at any age. Possibly the most feared lesions in FOP are those that involve the muscles of mastication. FOP flare-ups resulting in

limited mouth opening can follow the injection of local anesthetic for inferior alveolar nerve blockage in dental treatment.^{14,22}

Few clinicians are aware of the classic features of FOP and the specific association of preosseous soft tissue lesions with FOP are commonly mistaken for sarcomas or fibromatosis.⁵ Kitterman et al.²³ stated that nearly 90% of FOP patients worldwide are misdiagnosed and 67% undergo dangerous and unnecessary diagnostic procedures, such as incisional and excisional biopsies that lead to permanent harm and lifelong disability.

FOP should be diagnosed noninvasively as early as possible, based on the history and clinical and radiological findings.^{13,16,24} Imaging is crucial to make a proper diagnosis of FOP. Panoramic radiography, the lateral cephalometric (skull) projection, and oblique lateral mandibular ramus projections should be the first steps in the radiographic examination, although plain radiographs may be normal at the onset of FOP. After several weeks, calcification appears centrally within the soft tissue. Further calcification appears adjacent to the affected muscle and increases until the soft tissue mass




Fig. 4. Three-dimensional reconstructed CBCT images showing the elongation of the coronoid of the right TMJ through the skull base, which restricts mouth opening (*arrows*).

Fig. 3. Coronal and sagittal CBCT images showing a bifid right TMJ condyle, possibly owing to FOP (*arrows*).

is ossified completely.⁴ A periosteal reaction is frequently evident in the adjacent bone and may precede ossification of the soft tissue mass.²⁵

Panoramic radiography is a useful technique, because the posterior maxilla and coronoid process are seen. Radiographic projections, such as the transcranial view of the TMJs, submentovertex view, or Towne projection, do not provide adequate visualization of the coronoid process because of superimpositions. Moreover, the radiologist usually does not pay attention to the coronoid processes because the focus is on the TMJs. The lateral views will show coronoid hyperplasia, but cannot show the relationship between the hyperplastic segment and zygomatic arch.²⁶⁻²⁸ In our case, the elongation of the coronoid process was overlooked initially because of superimposition in the panoramic radiograph. However, CBCT led to the correct

diagnosis of exostosislike hyperplasia on the inner aspect of the zygoma, bulging into the infratemporal fossa.

Computed tomography is the modality of choice for assessing soft tissue calcifications and ossification bridges. The FOP ossification process starts cranially, progressing caudally. On CT, the ossification can be seen much earlier than on plain radiographs. Edema can be seen within and between the muscles. The initial calcification occurs around or adjacent to muscle, which can be reduced in size and then calcify by the third or fourth week. CT can readily distinguish large areas of bone that appear in the masticator muscles, fasciae, tendons, and ligaments with ossified bridges forming around joints. In the maxillofacial area, the muscles and fascial planes can be replaced by ossified sheets. Pseudojoints can form within the maxillofacial structures,⁴ as in our case. CBCT can be used instead of CT because of the lower radiation dose needed to evaluate this region. However, CBCT cannot delineate the soft tissues, so the early stages of FOP cannot be distinguished in soft tissues. Moreover, the edema around the muscles cannot be seen in CBCT images.

Magnetic resonance imaging (MRI) is another modality for visualizing FOP. Early lesions manifest as soft lesions displacing the fascial planes and these have a signal as intense as normal muscle on T1-weighted images, heterogeneously hyperintense on T2-weighted images, and show diffuse soft tissue edema. As the disease progresses and the lesion matures, the T2 hyperintensity decreases and areas of low signal intensity appear.^{4,25,29,30}

Bone scintigraphy can also be used for diagnosing FOP. Typically, active lesions take up 99 m-technetium diphosphonate, and this decreases as the lesions mature.²⁵⁻³¹ Ultrasound (US) is also useful for imaging FOP and can detect the early soft tissue changes. An early diagnosis can be made with US before any radiographic abnormalities appear. Vascularization is observed primarily in the early stages on US, and it tends to disappear as the lesion progresses.^{25,32}

The differential diagnoses of FOP should include fibrosarcoma, extraosseous sarcoma, Still's disease, ankylosing spondylitis myositis ossificans circumscripta, and osteodystrophy.^{5,13,16,25} Other pathologies should also be considered in the differential diagnosis, including traumatic myositis ossificans and rigid spine syndrome.^{3,6,9,12}

There is no known therapy effective against FOP. Medical therapy has limited success. Diphosphonates have been tried to reduce the ectopic calcification and inhibit reossification following surgery.³³ Retinoids, adrenocorticotrophic hormone, corticosteroids, dietary calcium binders, the intravenous infusion of ethylenediaminetetraacetic acid (EDTA), and warfarin are other modalities that have been used without success.¹⁶

Surgical procedures subject the patient to the risk of exacerbation and recurrence, triggering rapid progression of the disease.¹³ The bone removed in surgery tends to reform more abundantly than the original bone. Thus, elective surgery on the musculoskeletal system should be avoided. Immobility of the neck may also jeopardize anesthetic management in surgical emergencies. The anesthesiologist should evaluate FOP patients for possible difficult airway management. Dental treatment becomes more complicated because of the restricted mouth opening. Preventive dentistry, including periodic follow-ups, oral hygiene instructions, and nutritional counseling, is important. There is a clear relationship between the use of local anesthetics during dental treatments and subsequent trismus. Consequently, intramuscular anesthetics and mandibular blocks should be avoided.^{12,16,24}

CONCLUSIONS

The correct diagnosis of FOP is of great importance because there is no effective prevention or treatment at present. Clinical and radiological findings must be evaluated carefully in terms of symptoms. Conventional radiographs are useful for detecting ossifications, whereas panoramic radiography may not identify the ossifications because of superimposition and technical reasons. CT can clearly demonstrate the pattern of ossification and edema within or around muscles, whereas CBCT does not detect the edema or early changes in the

lesion. Although very rare, oral and maxillofacial radiologists should be aware of this disease.

REFERENCES

1. Magryta CJ, Kligora CJ, Temple HT, Malik RK. Clinical presentation of fibrodysplasia ossificans progressiva: pitfalls in diagnosis. *J Pediatr Hematol/Oncol* 1999;21:539-43.
2. Taylor JS. Stone man: fibrodysplasia ossificans progressiva. *Ala Med* 1984;54:24-7.
3. Kaplan FS, Le Merrer M, Glaser DL, Pignolo RJ, Goldsby RE, Kitterman JA, et al. Fibrodysplasia ossificans progressiva. *Best Pract Res Clin Rheumatol* 2008;22:191-205.
4. Tyler P, Saifuddin A. The imaging of myositis ossificans. *Semin Musculoskelet Radiol* 2010;14:201-16.
5. Kaplan FS, Xu M, Glaser DL, Collins F, Connor M, Kitterman J, et al. Early diagnosis of fibrodysplasia ossificans progressiva. *Pediatrics* 2008;121:e1295-300.
6. Mahboubi S, Glaser DL, Shore EM, Kaplan FS. Fibrodysplasia ossificans progressiva. *Pediatr Radiol* 2001;31:307-14.
7. Shore EM, Kaplan FS. Role of altered signal transduction in heterotopic ossification and fibrodysplasia ossificans progressiva. *Curr Osteoporos Rep* 2011. [Epub ahead of print].
8. Shore EM, Xu M, Feldman GJ, Fenstermacher DA, Cho TJ, Choi IH, et al. A recurrent mutation in the BMP type I receptor ACVR1 causes inherited and sporadic fibrodysplasia ossificans progressiva. *Nat Genet* 2006;3:525-7.
9. Herford AS, Boyne PJ. Ankylosis of the jaw in a patient with fibrodysplasia ossificans progressiva. *Oral Surg Oral Med Oral Pathol Oral Radiol Endod* 2003;96:680-4.
10. Gannon FH, Valentine BA, Shore EM, Zasloff MA, Kaplan FS. Acute lymphocytic infiltration in an extremely early lesion of fibrodysplasia ossificans progressiva. *Clin Orthop Relat Res* 1998;346:19-25.
11. Rocke DM, Zasloff M, Peeper J, Cohen RB, Kaplan FS. Age- and joint-specific risk of initial heterotopic ossification in patients who have fibrodysplasia ossificans progressiva. *Clin Orthop Relat Res* 1994;301:243-8.
12. Aslan G, Celik F, Görgün M. Unusual ankylosis of the jaw due to fibrodysplasia ossificans progressiva. *Ann Plast Surg* 1999;43:576-8.
13. van der Meij EH, Becking AG, van der Waal I. Fibrodysplasia ossificans progressiva. An unusual cause of restricted mandibular movement. *Oral Dis* 2006;12:204-7.
14. Leavitt BD, Teeples TJ, Viozzi CF. Submandibular space swelling in a patient with fibrodysplasia ossificans progressiva: a diagnostic dilemma. *J Oral Maxillofac Surg* 2009;67:668-73.
15. Smith R. Fibrodysplasia (myositis) ossificans progressiva. Clinical lessons from a rare disease. *Clin Orthop Relat Res* 1998;346:7-14.
16. Sendur OF, Gurer G. Severe limitation in jaw movement in a patient with fibrodysplasia ossificans progressiva: a case report. *Oral Surg Oral Med Oral Pathol Oral Radiol Endod* 2006;102:312-17.
17. Bridges AJ, Hsu KC, Singh A, Churchill R, Miles J. Fibrodysplasia (myositis) ossificans progressiva. *Semin Arthritis Rheum* 1994;24:155-64.
18. Lucotte G, Bathelier C, Mercier G, Gérard N, Lenoir G, Sémonin O, et al. Localization of the gene for fibrodysplasia ossificans progressiva (FOP) to chromosome 17q21-22. *Genet Couns* 2000;11:329-34.
19. Feldman G, Li M, Martin S, Urbanek M, Urtizberea JA, Fardeau M, et al. Fibrodysplasia ossificans progressiva, a heritable disorder of severe heterotopic ossification, maps to human chromosome 4q27-31. *Am J Hum Genet* 2000;66:128-35.

20. Sud AM, Wilson MW, Mountz JM. Unusual clinical presentation and scintigraphic pattern in myositis ossificans. *Clin Nucl Med* 1992;17:198-209.
21. Shafritz AB, Shore EM, Gannon FH, Zasloff MA, Taub R, Muenke M, Kaplan FS, et al. Overexpression of an osteogenic morphogen in fibrodysplasia ossificans progressiva. *N Engl J Med* 1996;335:555-61.
22. Luchetti W, Cohen RB, Hahn GV, Rocke DM, Helpin M, Zasloff M, et al. Severe restriction in jaw movement after routine injection of local anesthetic in patients who have fibrodysplasia ossificans progressiva. *Oral Surg Oral Med Oral Pathol Oral Radiol Endod* 1996;81:21-5.
23. Kitterman JA, Kantanie S, Rocke DM, Kaplan FS. Iatrogenic harm caused by diagnostic errors in fibrodysplasia ossificans progressiva. *Pediatrics* 2005;116:e654-61.
24. Geist JR, Bhatti P, Plezia RA, Wesley RK. Fibrodysplasia ossificans circumscripta of the masseter muscle. *Dentomaxillofac Radiol* 1998;27:182-5.
25. Parikh J, Hyare H, Saifuddin A. The imaging features of post-traumatic myositis ossificans, with emphasis on MRI. *Clin Radiol* 2002;57:1058-66.
26. Farman AG. Panoramic radiology: seminars on maxillofacial imaging and interpretation. Heidelberg: Springer-Verlag; 2007. p. 162-4.
27. White SC, Pharoah MJ. Oral radiology. Principles and interpretation. St. Louis: Mosby, Elsevier; 2004. p. 191-21.
28. Som MP, Brandwein M. Sinonasal cavities: anatomy, physiology and plain film normal anatomy. In: Som PM, Curtin HD, editors. Head and neck imaging. 3rd ed. St. Louis: Mosby; 1996. p. 91-2.
29. Wu JS, Hochman MG. Soft-tissue tumors and tumorlike lesions: a systematic imaging approach. *Radiology* 2009;253:297-316.
30. Papp DF, Khanna AJ, McCarthy EF, Carrino JA, Farber AJ, Frassica FJ, et al. Magnetic resonance imaging of soft-tissue tumors: determinate and indeterminate lesions. *J Bone Joint Surg Am* 2007;89:103-15.
31. Tulchinsky M. Diagnostic features of fibrodysplasia (myositis) ossificans progressiva on bone scan. *Clin Nucl Med* 2007; 32:616-9.
32. Abate M, Salini V, Rimondi E, Errani C, Alberghini M, Mercuri M, et al. Post traumatic myositis ossificans: Sonographic findings. *J Clin Ultrasound* 2011;39:135.
33. Bruni L, Giammaria P, Tozzi MC, Camparcola D, Scorpino F, Imperato C. Fibrodysplasia ossificans progressiva. An 11-year-old boy treated with a diphosphonate. *Acta Paediatr Scand* 1990;79:994-8.

Reprint requests:

Kaan Orhan, DDS, PhD
Ankara University
Faculty of Dentistry and Department of Oral, Tooth and Jaw
Radiology
06500, Beşevler
Ankara, Turkey
call53@yahoo.com