

Lecture 4

Common Anatomical Terms

Head to Toe (and All Parts
in Between)

Anatomical Terms in Animals

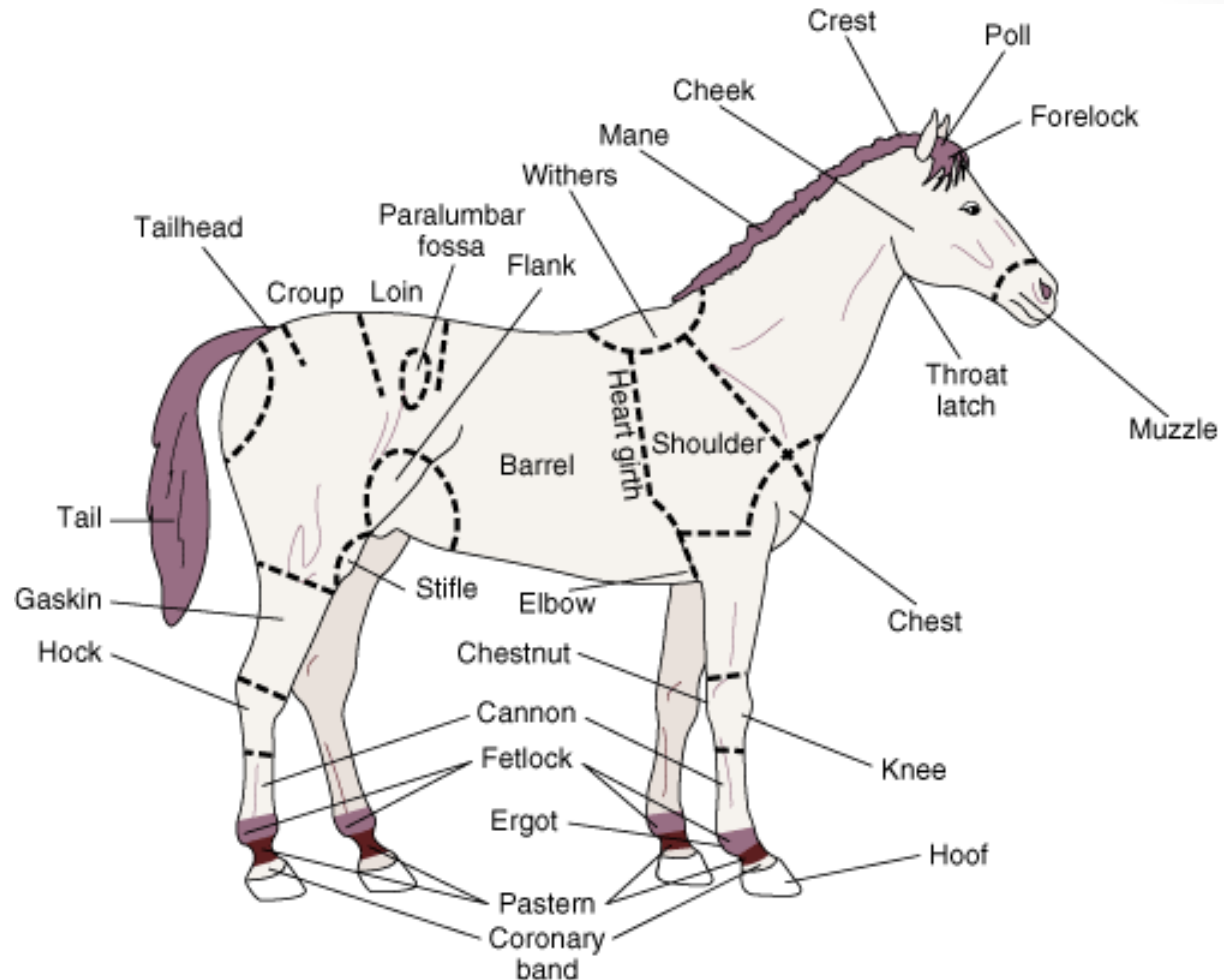
Asst. Prof. Dr. Wayne J. Fuller

Medical Terms for Various Species

- In veterinary medicine, there are many different species and many different terms used to describe animal anatomy and diseases.
- Reviewing species-specific terms will allow you to communicate effectively with clients.



Common Anatomic Terms for Equine Species



Horse (key parts)

- **Common Name**

Forearm

Knee

Cannon Bone

Splint Bones

Fetlock

Joint

Pastern

Long Pastern Bone

Short Pastern

Coffin Bone

Anatomical Term

Radius

Carpal Joint (Carpus)

3rd Metacarpal

2nd & 4th Metacarpal

Metacarpophalangeal

Interphalangeal Joint

1st Phalanx (Proximal)

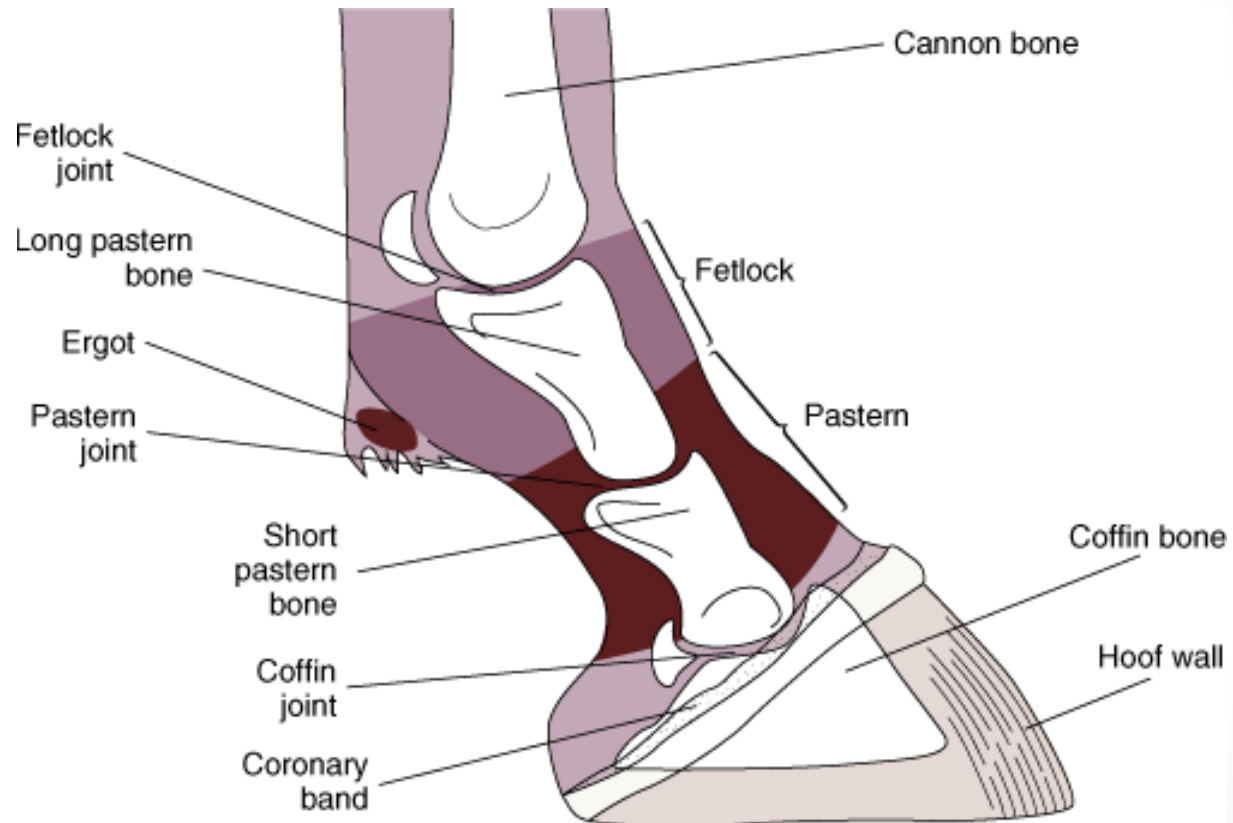
2nd Phalanx (Middle)

3rd Phalanx (Distal)

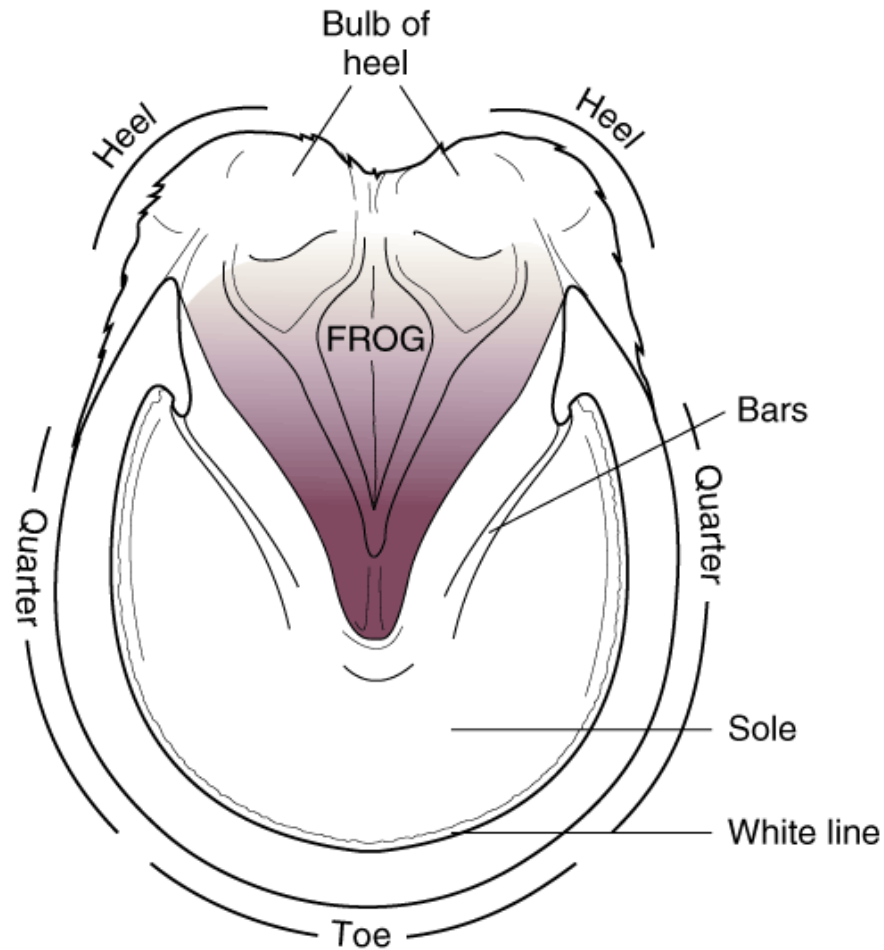
- **Radius** – The larger of the two bones of the forearm. The radius is the main central bone that attaches to the humerus at the approximal end and articulates with the carpal bones at the distal end.
- **Knee** – The horse's knee/carpus is made up of 2 rows of bones with four bones in each row. These bones are located very close to the horse's skin and there is very little movement within the bones. As humans, we have carpal bones as well, but ours are located in our wrist.
- **Cannon Bone** – This is the strongest bone in the horse's body. Articulates with the 2nd row of carpal bones and forms the carpal/metacarpal joint. Distally articulates with the long pastern bone and joins with the fetlock joint.

- **Splint Bones** – These bones in the horse are rudimentary structures and although they are present, they don't serve much of a useful purpose anymore as a result of evolution. The splint bones are attached by the interosseous ligaments to the cannon bone. As humans, we have metacarpal bones in our hands.
- **Fetlock** – The fetlock serves as an attachment part for the distal part of the suspensory ligament and is subject to a lot of stress and strain.
- **Pastern** – The portion of the horse's foot occupied by the first and second phalanges (#7 Long Pastern Bone and #8 Short Pastern). As humans, we have phalanges too: our fingers and toes.
- **Coffin Bone** – Or 3rd phalanx, is entirely enclosed by the hoof. The general shape of the bone conforms to the hoof itself and it is intimately related to the deep digital flexor tendon.

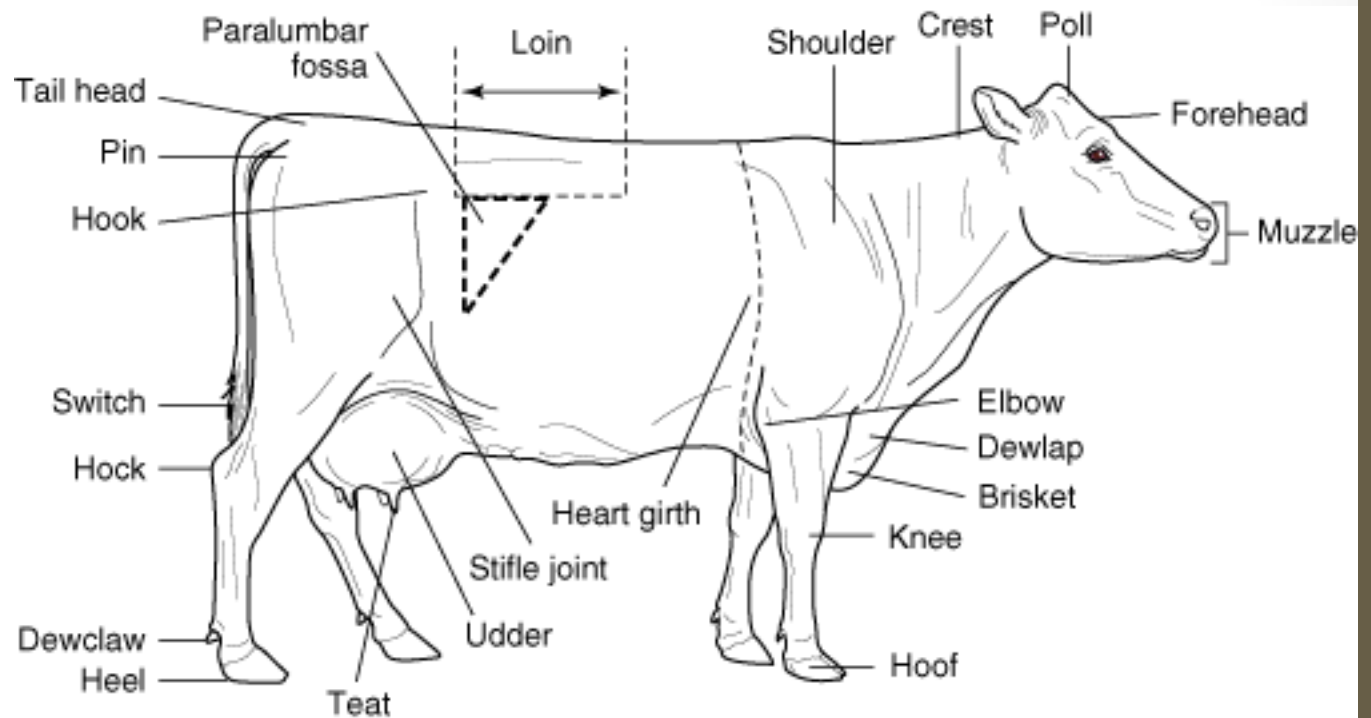
Common Anatomic Terms for the Equine Foot



Common Anatomic Terms for the Equine Hoof



Common Anatomic Terms for Cattle



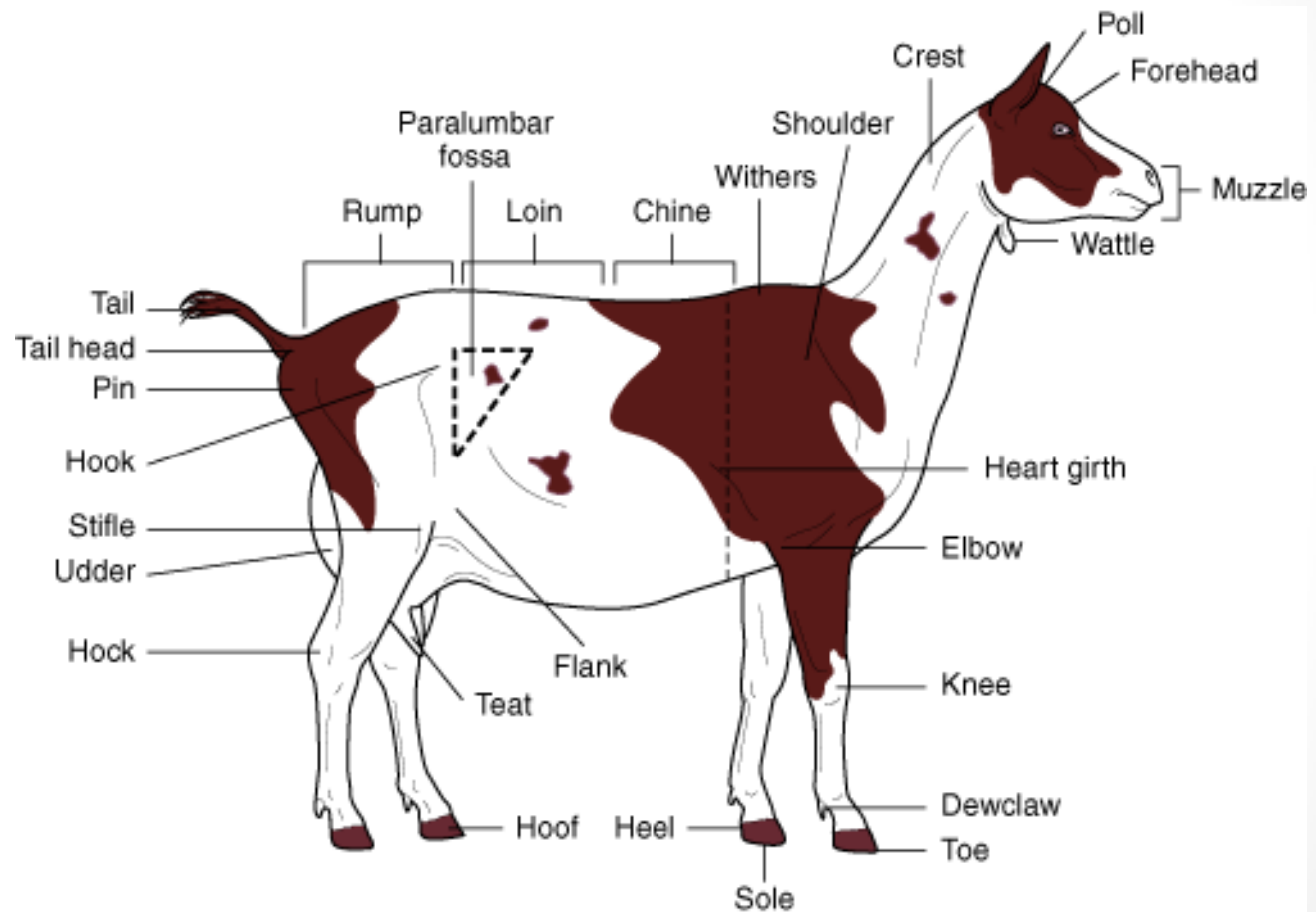
Cattle (Key parts)

- **Brisket** – Connective tissue, muscle, and fat covering the cranioventral part of the ruminants chest, between the forelegs.
- **Cannon Bone** – similar to horse, also known as the shin bone.
- **Coffin Joint** – same as in horses
- **Dew Claw** – projects caudally from the fetlock in ruminants.
- **Dewlap** – loose skin under the throat (can become pendulous in some breeds)
- **Dock** – solid part of the tail.
- **Elbow** - joint of the forelimb
- **Fetlock joint** – the same in horses
- **Flank** – same as in horse (between ribs and ilium)

Cattle (Key parts)

- **Loin** – Lumbar region of the back between thorax and pelvis
- **Muzzle** – two nostrils skin and muscles of the upper and lower lip
- **Paralumbar Fossa** – hollow area of the flank whose boundaries are lumbar vertebrae (dorsally), the last rib (cranially) and thigh muscles (caudally).
- **Stifle joint** – femorotibial and femoropatellar joint in quadrupeds
- **Switch** – tuft of hair at the end of the tail.

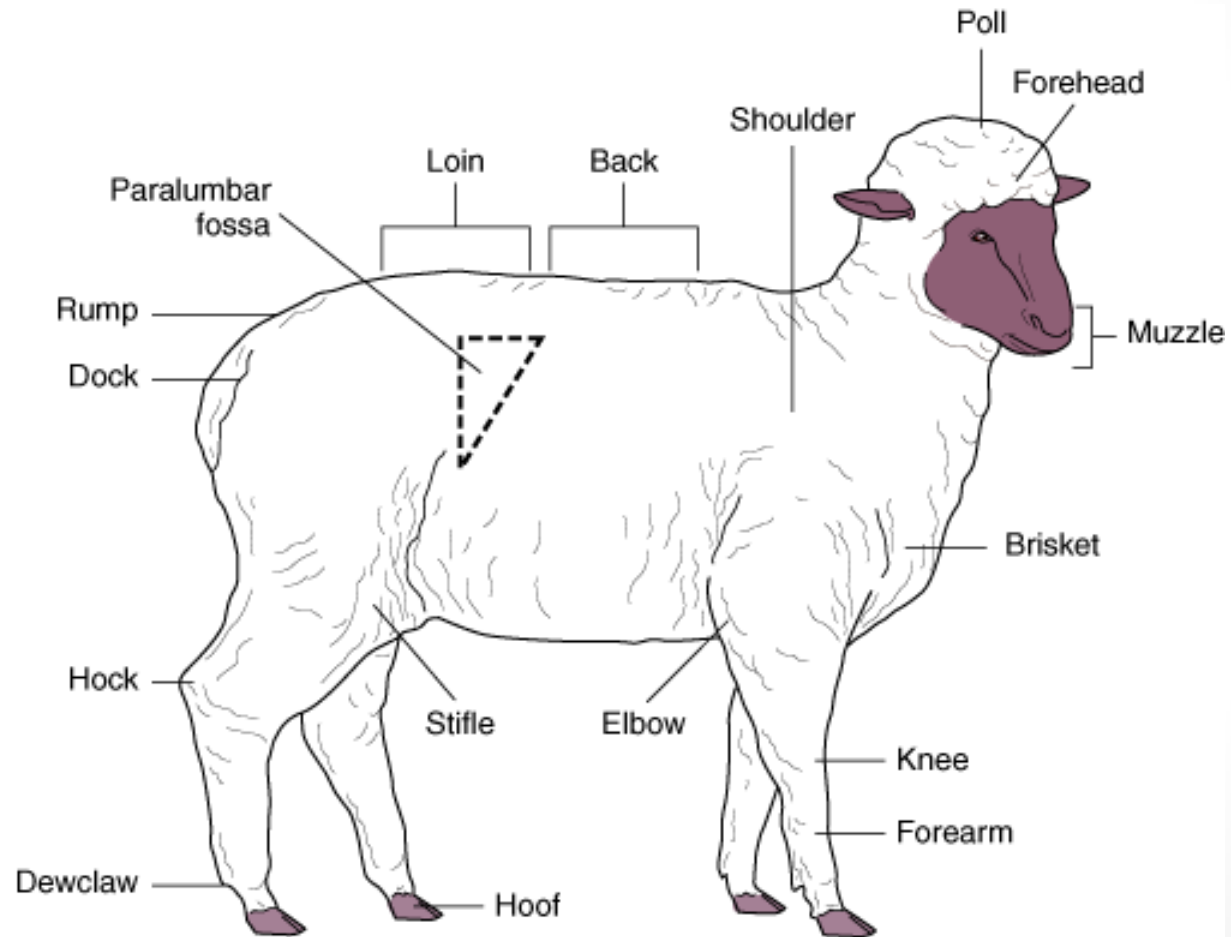
Common Anatomic Terms for Goats



Goat (Key parts)

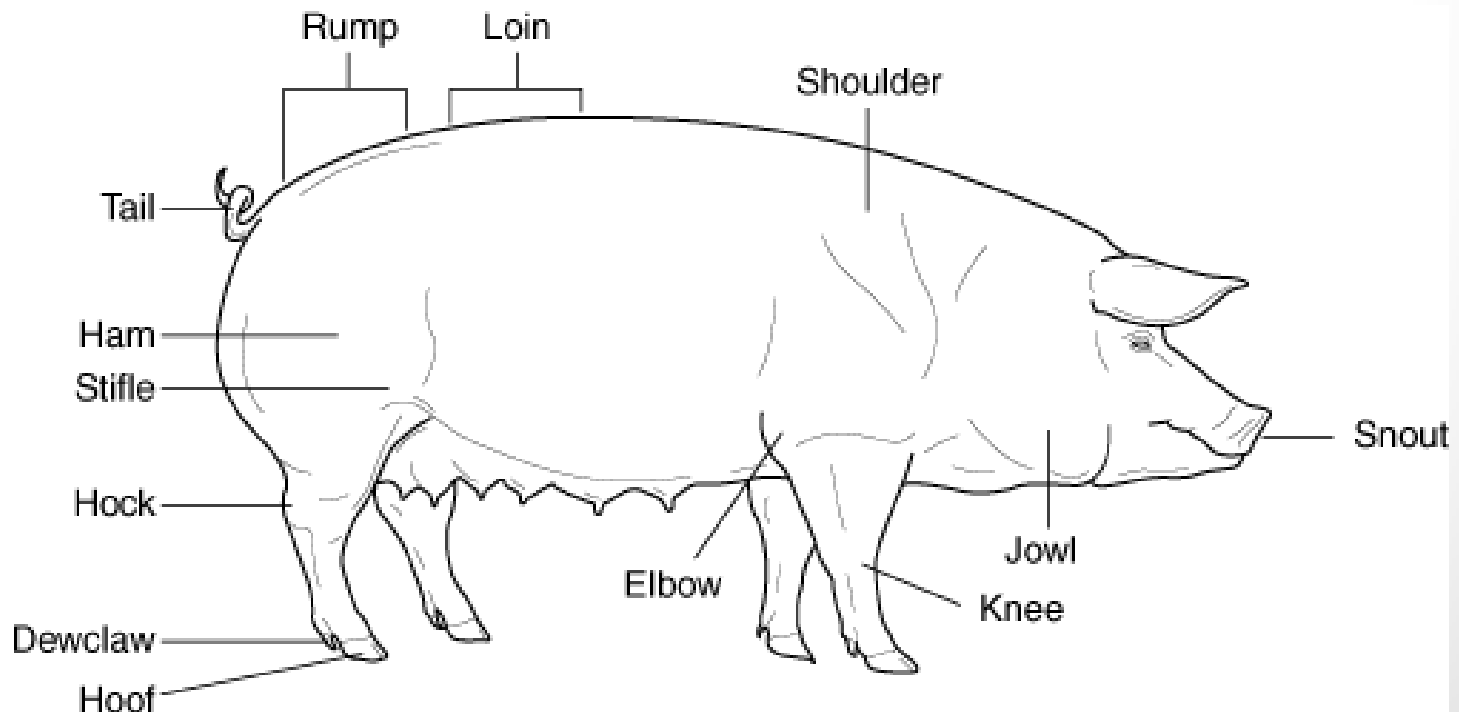
- **Chine** – thoracic region of the back
- **Hooks** – protrusion of the wing of the ilium on the dorsolateral area of ruminants
- **Horn butt** – poll region
- **Wattle** – appendages suspended from the head (usually under the chin).
- **Withers** – above the shoulder.

Common Anatomic Terms for Sheep

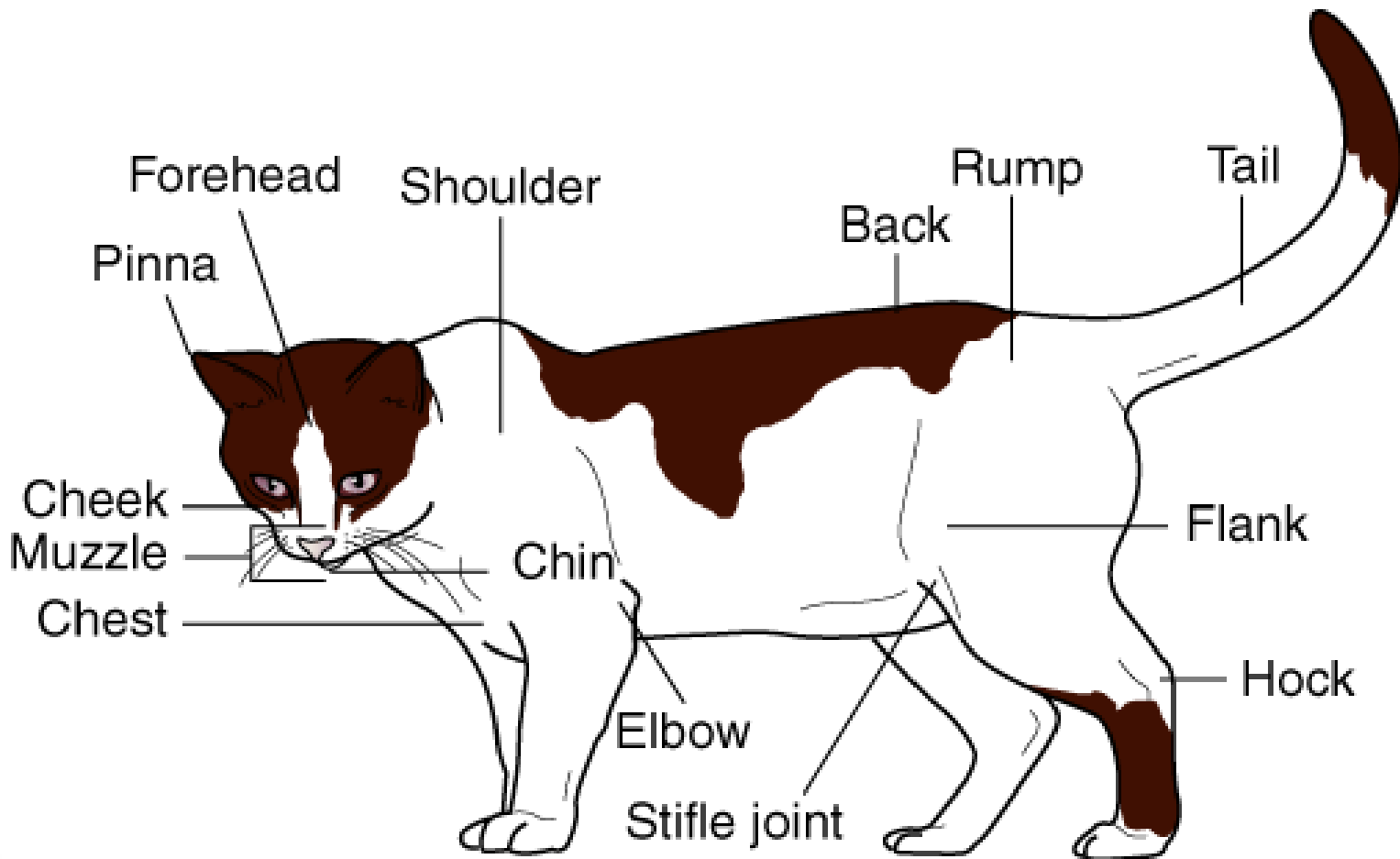


Common Anatomical Terms for Swine

- **Jowl** – fat or loose skin around the throat
- **Ham** – musculature of the upper thigh
- **Rump** – sacral to the tailhead region of the back
- **Snout** – upper lip and apex of the nose in swine



Common Anatomic Terms for Cats



Common Anatomic Terms for Dogs

